TRANSACTIONS

OF THE

OTOLOGICAL SOCIETY

VOL. II

UNIVERSITY OF LONDON
MEDICAL LIBRARY

Medical Deposit (27)

SHL
WITHDRAWN

94

U

TRANSACTIONS

OF THE

OTOLOGICAL SOCIETY

VOL. II.

TRANSACTIONS

OF THE

OTOLOGICAL SOCIETY

OF THE

UNITED KINGDOM

VOL. II

SECOND SESSION, 1900–1901

WITH LIST OF OFFICERS, MEMBERS, ETC.

EDITED BY

ARTHUR H. CHEATLE, F.R.C.S.

AND

WILLIAM MILLIGAN, M.D.

LONDON

J. & A. CHURCHILL

7 GREAT MARLBOROUGH STREET

1901

Digitized by the Internet Archive
in 2026

https://archive.org/details/transactions-of-the-otological-society-uk_1900-1901_2

TABLE OF CONTENTS.

PAGE

Officers and Council xiii

List of Members xv

Rules and Regulations xxii

First Annual Meeting, *December 3rd*, 1900, Reports of the Council, &c. 1

Communications, Specimens, and Cases :

First Annual Meeting, *December 3rd*, 1900.

A case of internal ear deafness, perversion of taste, and facial paralysis associated with herpes of the neck. By Arthur H. Cheatle 6

A case of cerebral tumour associated with bilateral deafness of nervous nature. By C. H. Fagge 8

A case of double ossiculectomy for chronic middle ear suppuration. By Richard Lake 13

Multiple epithelial grafting after the radical mastoid operation. By Herbert Tilley 15

Case of sarcoma. probably primary, of Eustachian tube. By F. C. Abbott 18

PAGE

A new portable electrical motor for surgical purposes. By C. A. Ballance and W. Milligan 20

Fourth Ordinary Meeting, *February 4th*, 1901.

(1) A case of cholesteatoma treated by the radical mastoid operation, with preservation of the lining membrane and Körner's plastic flap

(2) A case of cholesteatoma treated by the radical mastoid operation, with preservation of the lining membrane and Körner's plastic flap, with resection of cartilage. By Dundas Grant 23

Severe aural vertigo treated by operation. Cure. By H. Macnaughton-Jones 26

A patient upon whom the radical mastoid operation was performed for chronic suppurative disease of the epitympanum and adjoining mastoid cells. By W. Milligan 29

Cholesteatoma of mastoid. Radical cure. By P. De Santi 31

Mastoid abscess: extensive gangrenous emphysema of scalp tissues. Attico-antrectomy. Cure. By P. De Santi . 32

A patient on whom ossiculectomy was performed for perforation and cholesteatomatous formation in Shrapnell's membrane. By St. Clair Thomson . . . 34

Case of injury to the labyrinth. By P. Macleod Yearsley 36

Case of acute temporal bone septicæmia. By Charles A. Ballance 37

Microscopic section of epithelioma of cutaneous external meatus which was at first mistaken for mastoid disease. By Adolph Bronner 39

PAGE

A specimen and microscopical section of a case of tuberculosis of the middle ear lining membrane from an infant. By ARTHUR H. CHEATLE 42

A specimen of a gap in the handle of the malleus, probably congenital. By ARTHUR H. CHEATLE 42

Bullet wound through brain and cerebellum, leaving no after effects beyond loss of hearing on one side. By Sir WILLIAM DALBY 43

A fatal case of extra-dural abscess and cerebellar abscess. By C. H. FAGGE 43

Notes of a case of removal of an impacted meatal sequestrum facilitated by previous decalcification. By URBAN PRITCHARD 47

Tuberculous disease of the incus. By W. MILLIGAN . . 49

FIFTH ORDINARY MEETING, *March 4th*, 1901.

A case in which the complete post-aural operation was performed. By ARTHUR H. CHEATLE 50

A case of closed meatus following a Mauser bullet wound. By C. H. FAGGE 57

Case of acute meningitis following suppurative otitis media. Operation. Recovery. By LAMBERT LACK 61

Teaching diagrams for the explanation of Weber and Rinne's tests. By DUNDAS GRANT 63

Three specimens: (i) Absence of tendon of tensor tympani. (ii) Pigmented warty growth from the auricle of a woman, aged 50 years. (iii) Caries necrotica of the outer antral wall from a child, aged 4 years. By RICHARD LAKE 65

PAGE

A foreign body which had remained innocuously in the meatus for 26 years. By St. Clair Thomson . . 66

Suppurative otititis media, temporo-sphenoidal abscess. Operation. Hernia cerebri, maniacal excitement. Recovery. By Hugh E. Jones 67

Suppurative otitis media: caries of petro-mastoid: facial paralysis. Curetting operation. Death from convulsions twenty-eight hours later. By Hugh E. Jones . 73

Sixth Ordinary Meeting, *May* 11*th*, 1901.

Discussion on "The operative treatment of abscess when situated in the brain." Introduced by Charles A. Ballance 80

Extraordinary Meeting, *June* 10*th*, 1901.

A case of skin grafting after the complete mastoid operation. By W. C. Bull 117

Post-operative atresia of the meatus. By Richard Lake . 117

Woman, aged 35, in whom an acute mastoiditis has been followed by the spontaneous occurrence of a Stäcke-like operation. By St. Clair Thomson 120

A case of tuberculosis of the temporal bone in an adult. By Arthur H. Cheatle 123

A case of mastoid disease accompanied by septic thrombosis of the lateral sinus and post-pharyngeal abscess. By H. Secker Walker 126

PAGE

Notes, with specimen and microscopical sections, of two cases of carcinoma of the external auditory meatus. By ADOLPH BRONNER 130

Case of fatal hæmorrhage from the ear, with specimen. By W. MILLIGAN 131

Notes of a case of temporary loss of audition and equilibration from an overdose of quinine. By URBAN PRITCHARD 132

A red vegetable growth from the ear. By L. A. LAWRENCE 134

Notes of a case of papilloma of the auricle, with specimen and macro- and micro-photograph. By P. MACLEOD YEARSLEY 136

Central necrosis of a portion of the semi-circular canals. By W. C. BULL 136

Specimen of exfoliation of the cochlea. By C. H. FAGGE . 137

FIGURES.

1. An electrical motor. Mr. C. A. Ballance and Dr. William Milligan . . . *Page* 20
2. Temperature chart of a case of temporal bone septicæmia. Mr. C. A. Ballance's case . . . . . ,, 38
3. Section of tuberculous middle ear lining membrane. Mr. Arthur Cheatle's case . . *To face page* 42
4. Section of tuberculous incus. Dr. William Milligan's case . . . . . ,, 49
5 and 6. Teaching diagrams for the explanation of Weber's and Rinne's test. Dr. Dundas Grant . . . . . *Pages* 63 & 64
7. Photograph of patient after recovery from temporo-sphenoidal abscess. Mr. Hugh E. Jones's case . . . . . *To face page* 71
8. Photographs of a papilloma of the auricle. Mr. P. Macleod Yearsley's case . . . ,, 136

OFFICERS AND COUNCIL

OF

THE OTOLOGICAL SOCIETY OF THE UNITED KINGDOM.

President.

SIR WILLIAM DALBY.

Vice-Presidents.

URBAN PRITCHARD. THOMAS BARR.
GEORGE FIELD.

Hon. Treasurer.

ALPHONSO ELKIN CUMBERBATCH.

Hon. Librarian.

EDWARD CRESSWELL BABER.

Hon. Secretaries.

ARTHUR HENRY CHEATLE.
WILLIAM MILLIGAN.

Council.

CHARLES A. BALLANCE. EDWARD LAW.
ADOLPH BRONNER. PETER McBRIDE,
DUNDAS GRANT. ARTHUR SANDFORD.

LIST OF MEMBERS OF THE SOCIETY.

Honorary Member.

Professor ADAM POLITZER, Vienna.

EXPLANATION OF ABBREVIATIONS.

P = President.	*L* = Honorary Librarian.
VP = Vice-President.	*C* = Councillor.
T = Honorary Treasurer.	*S* = Honorary Secretary.

* = Original Members.

The abbreviations placed after a Member's name indicate offices which have been held by him.

ABBOTT, FRANCIS CHARLES, B.Sc., M.B., M.S., F.R.C.S., 44 Welbeck St., W. Aural Surgeon St. Thomas's Hospital. *Elected March* 5, 1900.

* *L* BABER, EDWARD CRESSWELL, M.B., 46 Brunswick Square, Brighton, and 57 Wimpole St., W. Surgeon Brighton, Hove, and Sussex Throat and Ear Hosp.

* BALL, JAMES BARRY, M.D., 12 Upper Wimpole St., W. Physician Throat, Nose, and Ear Department, West London Hosp.

* *C* BALLANCE, CHARLES ALFRED, M.B., M.S., F.R.C.S., 106 Harley St. Late Aural Surgeon St. Thomas's Hosp. *S.*

* BALLANCE, HAMILTON ASHLEY, M.D., M.S., F.R.C.S., 46 Prince of Wales Rd., Norwich.

BARNARD, HAROLD, M.B., M.S., F.R.C.S., 25 Welbeck St., W. Surgeon to Aural Depart. Metropolitan Hosp. *Elected December* 3, 1900.

* BARON, JOSIAH BARCLAY, M.B., C.M.(Ed.), 16 Whiteladies Rd., Clifton, Bristol. Physician for Diseases of Throat and Nose, Bristol General Hosp.

* *VP* BARR, THOMAS, M.D.(Glasg.), 13 Woodside Place, Charing Cross, Glasgow. Sen. Surgeon Glasgow Hosp. Diseases of the Ear, Lecturer on Aural Surgery Univ. of Glasgow, etc.

* BENNETT, FREDERICK WILLIAM, M.D., 25 London Rd. Leicester. Surgeon Ear and Throat Department Leicester Infirmary.

* BENSON, ARTHUR HENRY, M.A., M.B.(Dub.), F.R.C.S.I., 42 Fitzwilliam Square, Dublin. Ophth. and Aural Surgeon City of Dublin Hosp.

* BOND, JAMES WILLIAM, M.D., B.S., 26 Harley St., W. Phys. Hosp. for Diseases of the Throat, Golden Square.

* *C* BRONNER, ADOLPH, M.D.(Heidelb.), 33 Manor Rd., Bradford, Yorks. Surgeon Bradford Eye and Ear Hosp.

* BROWNE, JOHN WALTON, B.A., M.D., 10 College Square North, Belfast.

* BULL, WILLIAM CHARLES, B.A., M.B., F.R.C.S., 5 Clarges St., Mayfair. Aural Surgeon and Lecturer on Aural Surg. St. George's Hosp.

CATHCART, GEORGE CLARK, M.A., M.B., C.M.(Ed.), 35 Harley St., W. Assistant Surgeon London Throat Hosp. *Elected December* 3, 1900.

* *S* CHEATLE, ARTHUR HENRY, F.R.C.S., 117 Harley St., W. Assistant Aural Surgeon King's Coll. Hosp., Surgeon Royal Ear Hosp.

* *T* CUMBERBATCH, ALPHONSO ELKIN, M.B., F.R.C.S., 80 Portland Place, W. Aural Surgeon St. Bartholomew's Hosp. and Nat. Hosp. for Paralysed.

* *P* DALBY, SIR WILLIAM BARTLETT, B.A., M.B., F.R.C.S., 18 Savile Row, W. Consulting Aural Surgeon St. George's Hosp.

FAGGE, CHARLES HERBERT, M.B., M.S., F.R.C.S., 8 St. Thomas's St., London Bridge. Assistant Aural Department Guy's Hosp. *Elected March* 5, 1900.

* *VP* FIELD, GEORGE P., 34 Wimpole St., W. Consulting Aural Surgeon to St. Mary's Hosp.

FULLERTON, ROBERT, M.D., M.C.(Ed.), 24 Newton Place, Glasgow. Hon. Cons. Surgeon for Diseases of Throat, Nose and Ear Greenock Infirm.; Surgeon Throat, Nose and Ear Depart. Greenock Eye Infirm. *Elected March* 4, 1901.

* *C* GRANT, J. DUNDAS, M.A., M.D., F.R.C.S., 18 Cavendish Square, W. Surgeon Central London Throat and Ear Hosp., and Throat and Ear Department West End Hosp. for Nerv. Dis.

* GUILD, GEORGE TAYLOR, M.B., C.M.(Ed.), 164 Nethergate, Dundee. Surgeon Ear and Throat Depart Dundee Royal Infirm.; Lecturer on Diseases of the Ear and Throat Univ. St. Andrews.

* HARVEY, FREDERICK GEORGE, F.R.C.S.(Ed.), 4 Cavendish Place, W. Surgeon Hosp. for Diseases of the Throat, Golden Square.

HEATH, CHARLES J., F.R.C.S., 3 Cavendish Place, W. Surgeon Hosp. for Diseases of the Throat, Golden Square. *Elected March* 4, 1901.

* HILL, GEORGE WILLIAM, B.Sc., M.D., 28 Weymouth St., W. Aural Surgeon St. Mary's Hosp.

* HORNE, WALTER JOBSON, M.A., M.B., B.C. (Cantab.), M.R.C.P., 27 New Cavendish St., W. Surgeon Metrop. Ear, Nose and Throat Hosp.; in charge of Throat and Ear Department Farringdon Disp.

* HORSLEY, VICTOR, F.R.S., 25 Cavendish Sq., W. *C.*

* HOVELL, T. MARK, F.R.C.S.(Ed.), 105 Harley St., W. Aural Surgeon London Hosp. *C.*

* HUNT, JOHN MIDDLEMASS, M.B., C.M.(Glasg.), 55 Rodney St., Liverpool. Laryngologist Royal Infirm Liverpool.

* JAKINS, PERCY, M.D.(Dur.), 120 Harley St., W. Surgeon Central London Throat and Ear Hosp.

* JOHNSTON, ROBERT MCKENZIE, M.D., F.R.C.S.(Ed.), 2 Drumsheugh Gardens, Edinburgh. Assist. Surg. for Ear and Throat Royal Infirm. Edinburgh.

* JONES, HUGH EDWARD, 7 Rodney St., Liverpool. Senior Assist. Surg. Eye and Ear Infirm. Liverpool, Ophth. and Aural Surg. Royal Albert Edward Infirm. Wigan.

* JONES, HENRY MACNAUGHTON-, M.D. R.U.I., M.Ch., M.A.O.(Hon. Caus.), F.R.C.S.(I. and Ed.). 131 Harley St., W. Late Surgeon Eye, Ear and Throat Hosp., Cork.

* KELLY, ADAM BROWN, B.Sc., M.B., C.M.(Glasg.), 26 Blythswood Sq., Glasgow. Surg. Diseases of Throat, Nose and Ear, Victoria Infirm. and Bellahouston isp.

LACK, HARRY LAMBERT, M.D., B.S., F.R.C.S., 48 Harley St., W. Phys. Hosp. for Dis. of Throat, Golden Sq., Surg. Ear and Throat Dept. Child. Hosp. Paddington Green. *Elected May* 7, 1900.

* LAKE, RICHARD, F.R.C.S., 19 Harley St., W. Surg. Royal Ear Hosp. Surgeon Metrop. Ear, Nose and Throat Hosp.

* *C* LAW, EDWARD, M.D., C.M.(Ed.), 8 Wimpole St., W. Surg. London Throat Hosp.

* LAWRENCE, LAURIE ASHER, F.R.C.S., 4 Queen Anne St., W.

* LEWIS, CHRISTOPHER JOHN, M.D.(Brux.), 72 Newhall St., Birmingham. Hon. Surg. Birm. and Midl. Ear and Throat Hosp.

* *C* MCBRIDE, PETER, M.D., F.R.S.(Ed.), 16 Chester St., Edinburgh. Aural Surg. and Laryng. Royal Infirm. Edinburgh, Lect. Dis. Ear, Nose and Throat Univ. Edinburgh.

* MACEWEN, WILLIAM, F.R.S., 3 Woodside Crescent, Glasgow.

* MATHESON, FARQUHAR, M.B., C.M.(Aberd.), 11 Soho Sq., W. Surg. Royal Ear Hosp.

* *S* MILLIGAN, WILLIAM, M.D., C.M.(Aberd.), 12 St. John St., Deansgate, Manchester. Lect. Dis. of Ear Owens Coll. Manch., Hon. Surg. Manch. Ear Hosp., Aural Surg. Manch. Royal Infirm. *C.*

* PAGET, STEPHEN, F.R.C.S., 70 Harley St., W. Aural Surg. Middlesex Hosp.

PATERSON, DONALD ROSE, M.D.(Ed.), M.R.C.P.(Lond.), 18 Windsor Place, Cardiff. *Elected March* 5, 1900.

* PEGLER, LOUIS HEMMINGTON, M.D.(Ed.), 27 Welbeck St., W. Surg. Metrop. Ear, Nose and Throat Hosp.

PERMEWAN, WILLIAM, M.D., F.R.C.S., 7 Rodney St., Liverpool. Surgeon Throat and Ear Southport Infirm. *Elected December* 3, 1900.

* POLLARD, BILTON, M.B., B.S., F.R.C.S., 24 Harley St., W. Late Surg. in charge of Aural Department Univ. Coll. Hosp.

POTTER, EDWARD FURNISS, M.D.(Brux.)., 49 Queen Anne St., W. Surgeon London Throat Hosp. *Elected December* 3, 1900.

* *VP* PRITCHARD, URBAN, M.D.(Ed.), F.R.C.S., 26 Wimpole St., W. Aural Surg. King's Coll. Hosp. Professor Aural Surgery, King's Coll., Consult. Surg. Royal Ear Hosp.

* PURVES, WILLIAM LAIDLAW, M.D.(Ed.), 20 Stratford Place, W. Aural Surg. Guy's Hosp.

* *C* SANDFORD, ARTHUR W., M.D. R.U.I., 13 St. Patrick's Place, Cork. Lect. in Ophth. and Otol. Queen's Coll. Cork, Surg. Cork Ophth. and Aural Hosp.

SANTI, PHILIP ROBERT WILLIAM DE, F.R.C.S., 15 Stratford Place, W. Aural Surgeon and Lecturer on Aural Surgery Westminster Hosp. *Elected December* 3, 1900.

* SCATLIFF, JOHN MILTON ELLENBOROUGH, M.D.(Aberd.), 11 Charlotte St., Brighton. Hon. Surg. Brighton Hove and Sussex Throat and Ear Hosp.

* SHEILD, ARTHUR MARMADUKE, M.B., B.C.(Camb.), F.R.C.S., 4 Cavendish Place, W. Surg. Throat Department St. George's Hosp., Late Aural Surg. Charing Cross Hosp.

* Spicer, Scanes, M.D., B.Sc.(Lond.), 28 Welbeck St., W. Surg. Throat Department and Lect. Dis. of Throat St. Mary's Hosp.

* Stewart, William Robert Henry, F.R.C.S.(Ed.), 42 Devonshire St., W. Surg. Throat and Ear Department Gt. Northern Central Hosp., Consult. Surg. Lond. Throat Hosp.

* Story, John B., M.B., B.Ch.(Dub.), F.R.C.S.I., 6 Merrion Square North, Dublin, Ireland. Hon. Oc. and Aurist, Claremont Inst. for Deaf and Dumb.

* Thomson, St. Clair, M.D., M.R.C.P., F.R.C.S., 28 Queen Anne St., W. Phys. Throat Hosp. Golden Sq., Surg. Royal Ear Hosp.

* Tilley, Herbert, M.D., F.R.C.S., 89 Harley St., W. Surg. Throat Hosp. Golden Sq.

* Turner, Arthur Logan, M.D., F.R.C.S.(Ed.), 20 Coates Crescent, Edinburgh. Surg. Dis. Throat and Ear Deaconess Hosp. Edin., Surg. Edin. Throat and Ear Disp.

* Waggett, Ernest Blechynden, M.A., M.B., B.C. (Cantab.), 45 Upper Brook St., W. Assist. Surg. London Throat Hosp.

* Walker, Henry Secker, F.R.C.S., 45 Park Sq., Leeds. Assist. Ophth. and Aural Surg. Gen. Infirm. Leeds, Lect. Ophth. and Otology Yorkshire Coll. Leeds.

Westmacott, Frederick Hibbert, F.R.C.S., 8 St. John St., Manchester. Hon. Aural Surgeon Manchester Children's Hosp. Pendlebury. *Elected March* 4, 1901.

Whitehead, Arthur Longley, M.B.. B.S.(Lond.), 4 Park Square, Leeds. Hon. Ophth. and Aural Surgeon General Infirmary, Leeds. *Elected December* 3, 1900.

* Williams, Patrick Watson, M.D., 1 Victoria Sq., Clifton, Bristol. Phys. Throat Department Bristol Royal Infirm., Hon. Phys. Deaf and Dumb Inst.

* WOODS, ROBERT HENRY, B.A., M.D.(T.C.D.), 39 Merrion Sq. East, Dublin. Surg. Department Throat, Nose and Ear, Richmond &c. Hosps., Dublin.

* YEARSLEY, PERCIVAL MACLEOD, F.R.C.S., 10 Upper Wimpole St., W. Surg. Royal Ear Hosp.

RULES AND REGULATIONS.

1. Name of the Society.—The Society shall be called "The Otological Society of the United Kingdom."

2. Objects of the Society.—The objects of the Society shall be

(*a*) The exhibition and demonstration of patients, models, drawings, and specimens (microscopical or otherwise), illustrating the Anatomy, Physiology, Pathology, and Therapeutics of the Ear.

(*b*) The reading of papers and the discussion of questions in Otology, previously approved by the Council.

(*c*) The investigation by Committees—

(i) Of matters of public importance relating to Otology.

(ii) New methods of investigation or treatment of the diseases of the ear.

3. Constitution of the Society.—The Society shall consist of Ordinary and Honorary Members.

The Officers of the Society shall be elected from among the Ordinary Members, and shall consist of a President, not less than two, and not more than four, Vice-Presidents, a Treasurer, a Librarian, and two Secretaries, who, with six other Members, shall constitute the Council. At least one-fourth of the Council shall consist of Members not resident in London.

4. Election of Members.—Candidates shall be proposed on a form provided for the purpose, and signed by at least three members from personal knowledge, who shall state the grounds of their recommendation, which shall be, either

(*a*) Contributions to Otology.

(*b*) The charge of an Aural Clinic approved by the Council.

(*c*) Professional eminence.

The names of those proposed as new Members shall, in the first instance, be submitted to the Council, with whom the power shall rest of declining to allow the nomination to proceed.

The proposal paper shall be read at one ordinary meeting and the ballot shall be taken at the next meeting.

No election shall take place unless ten Members vote; one black ball in five shall exclude.

5. Form of Admission by the Chairman.—Members shall be admitted personally by the following form, after signing their names in the admission book, and thereby agreeing to abide by the rules of the Society, and paying their admission fee and first annual subscription.

Form of Admission.—"By the Authority and in the name of the Otological Society of the United Kingdom, I admit you a Member thereof."

6. Honorary Members.—The Council shall have the power of electing men of distinguished eminence in Otology as Honorary Members. The number of Honorary Members shall not exceed six.

7. Expulsion of Members.—The Council shall have the power of expelling from the Society any Member whose conduct or mode of practice is considered unworthy of the Society. Notice of the Council's intention to expel him shall be sent in writing to the address in the Society's books, and he may appeal to the Society, whose vote, under Rule 8, shall be final.

8. Appeal.—A member who appeals against the decision of the Council, under Rule 7, can be finally expelled only at a General Meeting specially called for that purpose, and of which a written notice shall have been sent to every Member at least fourteen days previously. At least twenty votes must be recorded, and four-fifths shall carry the expulsion.

9. Subscriptions.—There shall be an Admission Fee of One Guinea.

The Annual Subscription shall be One Guinea, payable to the Treasurer in advance at the date of the Annual General Meeting. Any Member whose subscription is six months in arrear shall be reminded of the same by the Treasurer, and if it be not paid within the current year he shall again be reminded by the Treasurer, and if he fail to pay his subscription, his name may be removed by the Council from the list of Members.

10. The Election of Officers and Council.—(*a*) All the Ordinary Members shall be summoned by letter to the Annual Meeting in December, notice being given a fortnight beforehand, and the hour of meeting being stated.

(*b*) The President, Vice-Presidents, Treasurer, Librarian, Secretaries and Council shall be elected by ballot at each Annual Meeting, and shall commence their duties on election.

(*c*) One-third of the Ordinary Members of the Council shall be replaced in rotation at each Annual Meeting by an equal number of Ordinary Members chosen from the Society at large.

(*d*) Balloting lists of the Members recommended by the Council to fill the vacant offices shall be prepared by the Secretaries, and forwarded, together with the summons to the Annual Meeting, to every Ordinary Member of the Society.

(*e*) Two Scrutineers, appointed by the President at the commencement of the Annual Meeting, shall receive the balloting lists during the first hour, at the end of which they shall report the result to the meeting.

(*f*) In the event of equality of suffrage the President shall determine by lot.

(*g*) If a member wishes to propose for ballot any candidate for office other than those whose names stand upon the list recommended by the Council, the name of such candidate, duly proposed by one Member and seconded by two other Members, shall be sent to the Senior Secretary at least a week before the Annual General Meeting.

(*h*) The Council shall have the power of filling up any vacancies which may occur in any of the offices of the Society between one Annual Meeting and another.

11. The President and Vice-Presidents.—The President shall regulate all the proceedings of the Society and Council, state and put questions, interpret the application of the rules and regulations, and decide every doubtful point. He shall sign the minutes of General and Council Meetings.

In the absence of the President, one of the Vice-Presidents, Treasurer, or some Member chosen by the meeting, shall perform his duties. The President and Vice-Presidents shall not serve for more than two consecutive years.

Every third President shall, if practicable, be resident out of London.

12. The Secretaries.—There shall be a Senior and a Junior Secretary elected for each session. The Senior shall retire at the end of each session, and shall, if the Society approve, be succeeded by the Junior. The Secretaries shall have the management of the correspondence of the Society and Council. They shall attend meetings. They shall take minutes, which they shall read at the following meeting. They shall notify to new Members their election. They shall have charge of, and keep a register of, all papers communicated, and shall be the Editors of the *Transactions* under the direction of the Council.

One of the Secretaries shall, if practicable, be resident out of London.

13. The Treasurer.—The Treasurer shall receive all moneys due to the Society, and make all payments ordered by the Council, keeping an account of all such receipts and payments. He shall keep a printed receipt book for subscriptions, and every receipt and cheque shall be signed by him. He shall submit to the Council a written report of the financial state of the Society, for presentation to the Annual General Meeting. All moneys shall be banked in the name of the Society, The Treasurer shall not hold office for more than five consecutive years.

14. Librarian.—The Librarian shall not hold office for more than five consecutive years.

15. The Council.—The Council shall have the management of the affairs of the Society. They shall meet as required during the session of the Society. Notice of the hour of meeting shall be transmitted by the Secretaries to each Member. Four shall form a *quorum*, and six shall form a *quorum* when the question of the expulsion of a Member has to be considered. The President or any three Members may call a special meeting.

They shall determine questions by vote, or by ballot if demanded, the Chairman having the casting vote. They shall call a special meeting or meetings after the close of the session to determine what communications and illustrations shall be published in the *Transactions;* they shall make such regulations and issue such orders as shall appear to them conducive to the good government of the Society, and to the proper management of its affairs, subject to the Rules of the Society. They shall appoint Investigating Committees as may be required.

16. The Society's Transactions.—The Transactions of the Society, under the designation of "*Transactions of the Otological Society of the United Kingdom*," shall be published in such manner as the Council may direct. The *Transactions* shall be presented to all Members of the Society who have paid their annual subscription. No Member whose entrance fee or subscription is in arrear shall be presented with the *Transactions*. The Council shall be empowered to present, in the name of the Society, copies of the *Transactions* to such scientific bodies as they may think fit.

17. Investigating Committee.—The Council shall, as occasion demands, appoint Committees of Members of the Society, and, if desirable, one or more Non-Members, for the purpose of investigating questions of importance in Otological science, and shall have authority to grant such sums of money as they may deem necessary for the expenses of these investigations. The reports of such Committees shall be presented to the Council to be dealt with as they may

deem most advisable. Such Committees shall be called "Investigating Committees"; they shall consist of not less than three Members. The Investigating Committees shall continue to act until they have reported on the subject referred to them, or been dissolved by the Council. Every Member who has acted on an Investigating Committee shall sign the final report, or shall state in writing his reason for declining to do so.

The report shall be first received and considered by the Council, which may be specially summoned for that purpose, and shall afterwards, with their sanction, be presented at an Ordinary Meeting of the Society.

The Council shall be informed by their Secretary of the retirement of any Member of an Investigating Committee, in which case the Council may at their discretion appoint another Member of the Society to fill the vacancy.

The Investigating Committees shall render to the Council an account of all money received by them for the purpose of their investigations.

The Council shall have the power to dissolve an Investigating Committee whenever they may deem it expedient.

18. Ordinary Meetings.—(*a*) The Ordinary Meetings of the Society shall be held on the first Monday, or some other day selected by the Council, at 4.30 P.M., in December, February, March, and May, in London or elsewhere, as the Council may decide.

(*b*) Each Member of the Society shall have the privilege of introducing a visitor at every Ordinary Meeting, on entering his visitor's name in the attendance book; but no visitor shall be introduced more than twice in the same session.

(*c*) The business of the Society at the Ordinary Meetings shall be:

(i) The reading of papers and report of cases.

(ii) The demonstration of cases.

(iii) The exhibition and examination of specimens (microscopical or otherwise), drawings, instruments, models, methods of treatment, and the discussion of Otological subjects.

(*d*) At the Ordinary Meetings of the Society nothing relating to its laws or management shall be brought forward.

(*e*) At Ordinary Meetings ten Members shall form a *quorum*.

(*f*) Additional Ordinary Meetings shall be held if the Council think them necessary.

(*g*) Papers (which must be written in form fit for printing) shall not, as a rule, be of such length as to occupy more than fifteen minutes in delivery. An abstract of each communication, for publication in the Medical Journals, shall be given to the Secretaries before the end of the Meeting at which the communication is read.

(*h*) Members wishing to read papers previously approved by the Council, or show cases, specimens, &c., shall, if possible, give notice thereof to the Secretaries ten days before the meeting.

(*i*) Papers on cases already published elsewhere by the author shall not, as a rule, be received.

(*j*) All papers shall be handed to the Secretaries immediately after being read.

(*k*) In any discussion, each Member taking part shall write on a form provided for the purpose an abstract of his remarks, which shall be given to the Secretaries before the end of the meeting.

(*l*) Every paper read before the Society shall be the exclusive property of the Society, and the author shall not be permitted to withdraw it, except by permission of the Council. If, in contravention to this rule, a paper read before the Society be published elsewhere by the author, it shall thereby be disqualified for admission into the Society's *Transactions*.

19. The Annual General and Special Meetings.—The Annual General Meeting of the Society, for the election of the officers and other Members of the Council, shall be held in December. All proposals to enact, alter or repeal rules shall be proposed by the Council only at the Annual or Special Meeting of the Society, notice of all such proposals being transmitted to every Member, together with the

summons to the Annual or Special Meeting. For the adoption of rules or changes so proposed, the votes of two-thirds of the Members present must be in favour of the proposal.

Any Member of the Society may suggest to the Council alterations in the rules, by letter addressed to the Secretaries.

A Special General Meeting may be called at any time by the Council, or at the written request of any ten Members, giving at least fourteen days notice by letter to every Member of the Society resident in the United Kingdom, of the time of meeting and the business upon which it is summoned, and no business shall be entered upon at such meeting except that which has been notified.

LIBRARY REGULATIONS.

1. The Library shall be open at the same hours as that of the Medical Society, viz., from 1 P.M. to 6 P.M. daily, except on Saturdays, when it will be closed at 3 P.M.

2. Members may obtain books at 11 Chandos Street, between those hours on signing a book provided for that purpose. But any books or periodicals may be placed by the Council on a separate list, such books not being allowed to be removed from the Library.

3. A book must be returned at the expiration of a fortnight if wanted by any other Member. The Librarian will in such a case write to the Member in whose name the book was taken out.

4. If the book be not returned within four days of such notice, a fine of 6*d*. will be charged for each day that the book is retained beyond such days of grace.

5. Members resident in the country can obtain books by writing to the resident Librarian, and transmitting the cost of postage. Such books are sent at the borrower's risk.

6. A member taking out a book will be held responsible for its being returned in good condition.

FIRST ANNUAL MEETING.

December 3rd, 1900.

The President, Sir WILLIAM DALBY, in the Chair.

The following gentlemen were elected Members of the Society:

Harold Barnard, George Clark Cathcart, William Permewan, Edward Furniss Potter, Philip de Santi, Arthur Longley Whitehead.

Mr. Stone and Mr. Secker Walker were appointed Scrutineers of the ballot for the election of Officers and Council.

The following Reports were presented and accepted.

REPORT OF COUNCIL.

The Council have great pleasure in presenting their Report. Since the inauguration of the Society three ordinary meetings have been held. The Investigating Committee appointed by the Council to inquire into the condition of the ears of London school children have been unable to commence work owing to the opposition of the School Board authorities.

The Society now numbers sixty-one members, and there are several candidates for election into the Society.

Prof. Politzer has been elected the first Honorary Member of the Society.

No member of the Society has been lost by death during the year, but the Science of Otology has to lament the decease of Prof. Gruber.

The meetings during the year have been well attended.

Great interest has been manifested in the discussion of the cases exhibited and the debating of important questions, The *Transactions*, which will be in the hands of members immediately, bear testimony to the admirable work done in the first session of the Society, and are an earnest of its future progress and prosperity.

LIBRARIAN'S REPORT.

The commencement of a Library has been made with the works presented to the Society during the past year, of which a list is appended. These have been carefully indexed in a card catalogue, which is kept at the Society's rooms, 11 Chandos Street, W. Further contributions of books are earnestly invited and may be sent to the Librarian, Mr. CRESSWELL BABER, at 11 Chandos Street, London, W., by whom they will be acknowledged.

LIST OF WORKS PRESENTED TO THE LIBRARY IN 1900.

DORAN, ALBAN, "Morphology of the Mammalian Ossicula Auditus." (*Trans. Linn. Soc.*, 2 Ser. Zool., vol. i. 1876.)

DORAN, ALBAN, "On the Auditory Ossicles of Rhytina Stelleri." (*Journ. Linn. Soc.*, Zool., vol. xvii. 1883.) (*The Author.*)

BARR, T., "Manual of Diseases of the Ear." 8vo. Glasgow. 1884.

BROCA, A., and LUBET-BARBON, F., "Mastoid Abscesses and their Treatment." (Translated by H. Y. CURTIS.) 8vo. London. 1897.

MCBRIDE, P., "Guide to the Study of Ear Disease." 8vo. Edinburgh. 1884.

POLITZER, A., "Text-book of the Diseases of the Ear and adjacent Organs." (Translated by T. P. CASSELLS.) 8vo. London. 1883.

MILLIGAN, W., "The Treatment of Chronic Suppuration of the Middle Ear by Excision of the Auditory Ossides." (*Brit. Med. Journ.*, vol. ii. 1893.)

MILLIGAN, W., "Two Cases of Cholesteatomata complicating Chronic Suppurative Otitis Media," with Remarks (*Liverpool Med. Chir. Journ.* 1894.)

MILLIGAN, W., "Tuberculous Disease of the Middle Ear." (*Med. Chron.* 1896.)

MILLIGAN, W., "Otitis Media Suppurativa Chronica. Cerebral Abscess." (*Journ. Laryng. Rhin. and Otol.* 1897.)

MILLIGAN, W., "Operative Treatment of Suppurative Middle Ear Disease." (*Liverpool Med. Chir. Journ.* 1897.)

MILLIGAN, W., "The Etiology and Treatment of Suppurative Disease of the Frontal Sinuses." (*Lancet*, i. 1898.)

MILLIGAN, W., "The Mutual Relationships and Relative Value of Experimental Research and Clinical Experience in Laryngology, Rhinology, and Otology." (*Brit. Med. Journ.*, vol. ii. 1898.)

MILLIGAN, W., "Recent Progress in the Treatment of some of the dangerous Complications of Suppurative Middle Ear Disease." (*Med. Chron.* 1899.)

MILLIGAN, W., "Some Observations upon the Diagnosis and Treatment of Tuberculous Disease of the Middle Ear and adjoining Mastoid Cells." (*Journ. Laryng. Rhin. and Otol.* 1899.) (*Dr. W. Milligan.*)

VALSALVA, ANT. MARIA, "De Aure Humana." (4to *Lug. Bat.* 1735.) (*Mr. L. A. Lawrence.*)

Transactions of the Sixth International Otological Congress, London, 1899. 8vo. London. 1900. (*The Editorial Committee.*)

1901.

HOVELL, T. MARK, "Diseases of the Ear." 2nd Ed. London. 1901. (*The Author.*)

GRAZZI, V., "Manuale di Otologia." Firenze. 1886. "Importanza del senso dell' olfatto in varie Industrie Agricole e presentazione del suo olfattometro." (*Est. Atti della R. Accad. dei Georgofili.* 1901.) (*The Author.*)

GUYE, A. A. G., "Over de Plica Vestibuli en het Aauzingen der Neusvlengels." (*Med. Lijds. v. Geneeskunde.* 1898.) (*The Author.*)

BURGER, H., "Aangeboren Misvorming der Vorschelp en Otoplastici." (*Med. Lijds. v. Geneeskunde.* 1894.) (*The Author.*)

BALLANCE, C. A., "The Operative Treatment of Abscess when situated in the Brain." London. 1901. (*The Author.*)

SCHMIEGELOW, E., "Beiträge zu den Funktionsuntersuchungen an Taubstummen in Dänemark." Kopenhagen and Berlin. 1901. (*The Author.*)

CONGRESS, OTOLOGICAL, *Transactions of the Sixth International.* 8vo. London. 1900. (*Duplicate Copy.*)
Catalogue of the Museum, ditto. 8vo. London. 1901. (*Two Copies.*)

GRUBER, JOS., "Lehrbuch der Ohrenheilkunde." 1st and 2nd Editions. (Translated and Edited by EDWARD LAW and COLEMAN JEWELL.) (*Dr. Law.*)

LIST OF EXCHANGES.

AUSTRO-HUNGARY, *Jahrbücher der Gesellschaft der Ungarischen ohren und Kehlkopfädzte.* Bd. vi. 1900. Budapest. 1901.

DENMARK, *Dansk oto-Laryngologisk Forening's Forhandlinger.* Copenhagen. Part iii. 1899. Vol. ix. 1900.

FRANCE, *Annales des Maladies de l'Oreille, du Larynx, du Nez, et du Pharynx.* Paris. 1901.

Archives Internationales de Laryngologie, d'Otologie et de Rhinologie. Paris. 1901.

Revue Hebdomodaire de Laryngologie, d'Otologie et de Rhinologie. Bordeaux. 1901.

GERMANY, *Monatsschrift für Ohrenheilkunde somie für Kehlkopf-, Nasen-, Rachen-, Krankheiten.* Berlin. 1901.

Verhandlungen der Deutschen Otologischen Gesellschaf. auf der Neunten Versammlung in Heidelberg, 1900. Jena. 1900.

HOLLAND, *Jaarverslag der Gemeentelijke (Universiteits) Poliklinick voor Keelziekten.* Amsterdam. 1897.

Niederländische Gesellschaft für Hats-, Nasen-, und Ohrenheilkunde. i. 1893–ix. 1900.

ITALY, *Bolletino delle Malattie dell' Orecchio, della Gola, e del Naso.* Firenze. 1901.

Archivio Italiano di Otologia, Rinologia e Laringologia. Torino. 1901.

UNITED STATES OF AMERICA, American Otological Society. *Transactions* from vol. i. 1872. (Vols. ii. and iii. incomplete.) Boston.

Archives of Otology. Vol. xxx. New York.

TREASURER'S REPORT.

All the Members have paid their subscriptions.

After paying all expenses including the installation of light, etc., we are only £2 6*s.* 3*d.* in debt.

With regard to the expense of printing the *Transactions* the Treasurer has no doubt that this can be met by next year's receipts, which will also wipe out the small deficit left from this year.

Dr. MACNAUGHTON JONES and Mr. MACLEOD YEARSLEY acted as Auditors.

The following alterations of and additions to the Rules and Regulations were passed:

1. That Clause (*b*), Rule 4, shall in future read "The charge of an aural clinic approved by the Council."

2. That in Clause (*c*), Rule 10, the word "ordinary" be placed before "Members of the Council."

3. That the following clause be added to Rule 10: "If a Member wishes to propose for ballot any candidate for office other than those whose names stand upon the list recommended by the Council, the name of such candidate, duly proposed by one Member and seconded by two other Members, shall be sent to the Senior Secretary at least a week before the Annual Meeting."

4. That the following clause be added to Rule 11: "Every third President shall, if practicable, be resident out of London."

5. That the following clause be added to Rule 12: "One of the Secretaries shall, if practicable, be resident out of London."

The Scrutineers reported that the following Officers and Council were elected:

President: Sir WILLIAM DALBY.
Vice Presidents: Dr. URBAN PRITCHARD, Dr. THOMAS BARR, Mr. FIELD.
Hon. Treasurer: Mr. CUMBERBATCH.
Hon. Librarian: Mr. CRESSWELL BABER.
Hon. Secretaries: Mr. ARTHUR H. CHEATLE and Dr. MILLIGAN.
Council: Mr. CHARLES A. BALLANCE, Dr. ADOLPH BRONNER, Dr. DUNDAS GRANT, Dr. LAW, Dr. MCBRIDE, Dr. SANDFORD.

A case of internal ear deafness, perversion of taste, and facial paralysis associated with herpes of the neck.

By ARTHUR H. CHEATLE.

The patient was an unmarried woman aged 27 years, who had never suffered from anything wrong with her ears until the present attack.

As she was unmarried it was difficult to examine her with reference to syphilis; but she had pigmented scars on both legs, the result of ulcers; and a smooth ulcer, the size of a threepenny bit, was present on the calf of the left leg.

She was sent to King's College Hospital by Dr. W. R. BRYETT on November 12th, 1900.

A fortnight previously she noticed some "blisters" immediately on the right of the middle line, on her neck below the chin and above the sternum; more spots appeared, the trouble apparently spreading backwards in lines to the back of her neck, where to the right of the middle line several large ones appeared; an isolated one came immediately in front of the lobule of the ear, and another on the upper part of the chest. The superficialis colli from the second and third cervical nerves and internal division of the posterior

division of the third cervical nerve apparently explained the course.

Shortly after the spots appeared severe neuralgic pain was experienced in the back of the neck and behind the ear together with a roaring noise and deafness in the right ear, and right facial paralysis. The right ear "burned fearfully." At the same time she noticed she was unable to walk straight towards any object.

A week after the facial paralysis, etc., came on she had an attack of giddiness which lasted two days, and she vomited nine times on the first day. There had not been any vomiting or marked vertigo since, but she was still unable to walk straight.

Two days before coming she noticed that everything she ate had a bitter taste; this symptom ceased on the day on which she came.

On examination there was right facial paralysis, the scars of the herpes were visible, but all pain had ceased. No signs of congenital syphilis.

The left ear was normal.

The right membrane was slightly retracted. No herpes on auricle, in meatus or on the membrane.

Nose nil.

Naso-pharynx nil.

The uvula, in mid-line and moving freely.

The watch 2 feet R. 3 in. Voice comparatively better than watch. Galton's whistle heard throughout but indistinctly. Tuning-fork A > B, and on nose heard better on the left side. — 2″ with Gardiner Browne's test.

There was marked unsteadiness on standing with the eyes closed, and on attempting to walk along a straight line there was a tendency to lurch to the right.

The pupils were equal and reacted to light.

Reflexes normal.

Sensation normal.

As these symptoms, omitting the herpes, are sometimes observed in the tertiary stage of syphilis, she was placed on iodide with counter-irritation behind the ear, and improvement was taking place.

Politzer notices herpes of the auricle associated with facial paralysis in a few cases.

Gruber notices herpes of the auricle associated with deafness and subjective auditory sensations even if the external auditory canal be not affected.

The patient herself attributed the trouble to exposure to draughts while at her work.

Mr. CHEATLE said he would like to know whether other members had met with similar cases. Certainly the symptoms associated with his case were very rare.

Dr. MILLIGAN asked whether the patient had had any previous attack of Russian influenza. He considered the case to be one of peripheral neuritis probably post-influenzic.

Mr. BALLANCE agreed with the opinion expressed by Dr. MILLIGAN.

Mr. CHEATLE replied that the patient had not had influenza lately, but she was exposed to cold a few weeks before the present symptoms came on.

A case of cerebral tumour associated with bilateral deafness of nervous nature.

By C. H. FAGGE.

M.B., *æt.* 19, female, a general servant, was admitted, under Dr. HALE WHITE, into Mary Ward, Guy's Hospital, on October 15th, 1900, for vomiting and dizziness in the head.

Family History.—Patient's mother had discharge from ears and nose, and used to have much vomiting and giddiness. Patient had two sisters and three brothers, who yielded no data bearing on the present question. No suspicion of congenital syphilis.

Personal History.—Patient had measles as a child. She had never had otorrhœa, and her hearing, as volunteered by her relations, was perfectly normal, until about Christmas,

1898, when she began to be deaf in the left ear; she now suffered from sickness in the morning and from noises and giddiness in the head. Some time later she became gradually deaf in the right ear. She was admitted into the Saffron Walden Hospital on May 14th, 1901, and remained in five weeks. A month later her eyes became defective, first the left, and then the right becoming blind. Later she went into Moorfields without relief.

Condition on Admission.—T. 98, P. 78, R. 18. Rather wasted. Blind in both eyes and deaf in both ears, complaining of noises and dizziness. No paralysis; she says she falls slightly to left side when walking. When seen walking she walks naturally, does not drag one foot, no spasticity, no falling or tremors. There is no alteration of sensation; she has frontal and occipital headache. Reflexes are normal. Her mental faculties are rather slow, though her memory is good. Speech and deglutition normal. Eyes: pupils widely dilated, no photophobia or nystagmus; she cannot distinguish objects, but has perception of marked variations in light, such as throwing a light on her cornea for ophthalmoscopic examination. Discs are large, whitish with blurred feathery edges; veins are distended, tortuous, and in places the course of the vessels is obscured by lymph: central part of disc is filled up.

Hearing, nil to voice; W. $\frac{\text{R. } 1\frac{1}{2}}{\text{L. } 0}$.

Patient vomits rather frequently in the morning. She was put on potass. iod. grs. v. t.d.s.

October 13th.—Headache rather less.

October 19th.—Pot. iod. increased to grs. xxv. t.d.s.

October 24th.—Pot. iod. increased to grs. xlv. t.d s. Headache continues, but very little sickness.

October 27th.—Headache more severe. Pot. iod. grs. 100 t.d.s.

November 1st.—Neuritis is passing into well-marked atrophy.

November 10th.—Patient appears completely deaf. Watch (36″) not heard in either ear. T. F. not heard in either ear on mastoid. P. and T. both normal. Cannot hear by voice at

all. Intelligence acute. Dr. HALE WHITE has decided not to recommend operation as he cannot localise tumour, and does not think intracranial pressure much increased: further, he thinks optic atrophy is too far advanced for trephining to remedy blindness at all.

November 30th.—Sickness continues; headache is now less marked, but variable. Optic atrophy is well marked in both eyes. Tests for hearing give the same results.

Remarks.—I was asked to see the case by Dr. HALE WHITE, as one of intracranial tumour, with the hope that owing to the associated nerve deafness some light might be shed upon the localisation of the tumour.

I have brought the case before this Society, with the kind permission of Dr. HALE WHITE, in order that the Members may, if possible, supply the knowledge which I lacked.

There is, as far as I can see, no reason to doubt the first part of the diagnosis of intracranial tumour, the Hippocratic signs of which have been present throughout, and I think the balance of evidence is much in favour of this, as against the next most probable—some form of meningitis.

If the presence of a tumour be acknowledged in the absence of any history and signs of syphilis, and failure of potass. iod. in large doses, I think we must expect that form of tumour which is most common—a gliosarcoma.

As to its localisation, I am in favour of cerebellum, because of (1) the early evidence of double optic neuritis, and its fairly rapid transition into atrophy; * (2) of regions outside the motor area it is the commonest position (Dr. Byrom Bramwell, *Brain*, 1896, in 7/40 cases); (3) the normal mental condition of the patient; (4) giddiness; (5) persistence of vomiting: though I admit that the absence of nystagmus and the fairly natural gait are against my view.

Because of these and other symptoms I would attempt to locate the tumour in the left lateral cerebellar lobe (intramedullary of Dr. Beevor).

We now come to the important point in the discussion. How could such a tumour cause bilateral nerve deafness?

* Marcus Gunn, *Brain*, 1898, 21, p. 333.

Excluding the probability of the involvement of the left cochlear fibres and the crossed Rt. vestibular fibres in the left cerebellum, according to Freud's researches (*vide* Politzer, 94, p. 630), it seems unlikely that both 8th nerves, and they alone, would be involved as they pass to the internal auditory meatus either by direct pressure from a tumour or by the secondary basal meningitis, which is not an uncommon complication of such tumours.*

When my thoughts had reached this stage, I was forced for an explanation of involvement of both auditory nerves to regard it as an indication, just as optic atrophy and headache, of general increased intracranial pressure. True in this case headache and other signs do not suggest much increased pressure, but I would not be so definite, and would suggest that the amount of increase of pressure sufficient to produce optic atrophy may also produce nerve deafness, which, like the former, should be bilateral and first involve the nerve of the same side as the tumour.

There are many theories as to the mode of causation of this optic neuritis, and so there might be for such nerve deafness. Spreading inflammation, as I have said above, seems improbable, and I should like to suggest that the increased pressure in the subarachnoid space acts directly on the perilymph in the scala tympani and vestibuli, probably through the aqueductus cochleæ, and possibly also through the sheath of the auditory nerve which connects these cavities (Quain).

Why is not such a condition more common?

Bramwell (*loc. cit.*) notes two cases out of seven, one of which is very like mine.

I think the following considerations support my view. Moos,† "Archives of Otology," 1894, vol. xxiii. p. 315: Case of brain tumour involving 8th nucleus, but also as accounting for deafness, there was osteoid and connective tissue hyperplasia in aqueductus vestibuli and in semicircular canals; Reissner's membrane was depressed towards

* Marcus Gunn, Brain, 1898, p. 334.

† *Zeitschrift für Ohrenheilkunde*, 1894.

the ductus cochlearis, and the membrane of the round window was convex outwards.

Theoretically he had dealt with this question at the International Otological Congress at Basle in 1884,* when he practically enunciated the pathology I suggest for my case. Physiologically, Ch. Burnett (*Archives für Aug. u. Ohrenheilkunde*, 2, 1872), showed that raised intercranial pressure caused diminished bone conduction for high and then for low notes. (High notes in lower round of cochlea.) Moos says this is followed by brain tumours. Gowers (*Lancet*, i. 1879, 365) quotes a case of sarcoma found post mortem between posterior ends of optic thalami, above crura, involving corpora quadrigemina.

He writes: "The most noteworthy symptom in the case is the paralysis of the auditory nerves. . . . As regards the auditory nerves, no lesion of the trunks was found to explain it. They were perfectly normal, and there was no trace of lymph or of pressure. A possible explanation may be that the paralysis was due to the damage to the most superficial fibres of the tegmentum of the crus cerebri.

"If these contain the fibres from the auditory nerve, the symmetrical paralysis would be explained, since the most superficial of each were damaged. The point is mentioned as worthy of attention in any future cases of the kind."

Mr. Cheatle asked what were the characteristics of the vertigo which the patient had; was it true auditory vertigo? With regard to increased tension, a term which Mr. Ballance objected to because it could not be measured, he thought that did seem to account for the vertigo. If the patient died, he hoped Mr. Fagge would get sections of the labyrinth on both sides, for comparison, and a full post-mortem report.

Dr. Milligan asked whether puncture of the lumbar theca had been performed, and the fluid analysed. He did not think the symptoms warranted the diagnosis of tumour, but of

* *Berliner Klinische Wochenschrift*, 1884, 45; *Zur. Genes. der Gehors. bei Gehirntumoren.*

basic meningitis, which was slowly increasing and possibly of syphilitic origin.

Mr. FAGGE, in reply, said, regarding the character of the vertigo, the patient was so deaf and ill that he was unable to make her understand anything. She, however, once volunteered the statement that things went round her.

In answer to Dr. MILLIGAN, no lumbar puncture had been performed. The case was not his own, and therefore he could hardly suggest diagnostic procedures. He would take care at the post-mortem to procure both temporal bones. On the patient's admission the pulse was 78, and had remained between 78 and 90; it had always been regular and of good volume.

A case of double ossiculectomy for chronic middle ear suppuration.

By RICHARD LAKE.

Mrs. T., *æt.* 33, was brought by Dr. F. V. DENNE on July 12th, 1900, with the following history. She had had scarlet fever when two years of age, with subsequent otorrhœa. She had suffered with no other serious illness before marriage, which took place at the age of 15, but since then has had pneumonia, nephritis and undoubted specific trouble. She had been deaf since the scarlet fever and was treated at three different hospitals at the age of 12. The ears got better and she left them alone, though the discharge had never ceased in either ear for long at a time.

About May this year she found that both ears were discharging, and she also commenced to have otalgia and attacks of vertigo.

When sent to Mr. Lake the right membrane was all destroyed except an outer rim, the left was perforated in the lower part and had a second perforation which led up into the antrum.

She was under treatment for three months, but as the pain and giddiness and discharge were still complained of,

the ossicles, remains of membrane and outer attic walls were removed on October 2, under ether narcosis. The incus was absent on the left side.

The right ear was healed in four weeks, and a few weeks after, a small piece of bone was removed from the left ear, left behind at the time of operation, after which the ear rapidly healed.

The patient thought she is a little more deaf than she was but was not sure. The after treatment was left entirely to Dr. DENNE.

The PRESIDENT said the middle ears of the patient seemed very dry and satisfactory, and resembled very much many cases he saw some years ago, which were brought over as show cases by Mr. SEXTON. He understood from Mr. LAKE that of every hundred such cases eighty got well. Sometimes the hearing was a little better afterwards, sometimes not quite so good. Practically one could never tell what was going to be the condition of the hearing after removal of ossicles.

Dr. W. HILL asked whether Mr. LAKE had only practised ossiculectomy, or whether he curetted the attic afterwards. Also, did Mr. LAKE remove the outer wall of the attic under a general anæsthetic?

Mr. BRONNER asked whether insufflation with iodoform had been used six or seven times a day on one side, and removal of the bone carried out on the other, to see which healed up first. He thought such might well be tried in a double case.

Mr. FAGGE asked whether Mr. LAKE had ever removed ossicles under a local anæsthetic.

Dr. MILLIGAN asked whether, in this case, any preliminary antiseptic treatment was adopted; or did Mr. LAKE practise ossiculectomy in the first instance? He presumed it was a case of attic disease.

Mr. BULL said he understood Mr. LAKE burred away the outer wall of the attic with a drill, and therefore this was not a true case of ossiculectomy; more than removal of the ossicles was done.

Mr. CHEATLE said they had come to the conclusion that the outer attic wall should be removed when ossiculectomy was performed.

Mr. LAKE, in replying on the discussion, said the discharge had lasted thirty years, since the patient was a child, and the original cause was scarlet fever. There was much perforation leading into the attic and antrum on the left side, the membrane was destroyed on the right side, and the incus was incomplete on both. With regard to curetting the attic, he could hardly help doing so. In such cases he always removed the external attic wall, and cleared everything out he could. He did not think one could remove the external attic under a local anæsthetic. With regard to Dr. BRONNER'S suggestion, he did not think patients would attend six times a day for the application of a local antiseptic. The present patient had been under treatment with general antiseptics for three months before surgery was attempted. The left side had healed, but there was a great deal of local pain.

Multiple epithelial grafting after the radical mastoid operation.

By HERBERT TILLEY.

B. H., male, *æt.* 46, sought advice for bilateral deafness associated with a chronic discharge from right ear. There was occasional earache on this side. Patient could not hear a loud-ticking watch in either ear. Tuning-fork only heard by bone conduction, and this very deficient.

Examination showed the left tympanic membrane opaque, retracted and adherent in places to the inner wall of tympanum. The right cavity contained small granulations, and the remains of a carious incus could be felt in the upper and posterior quadrant. After failure to cure the discharge by ordinary measures the remains of the malleus and incus were removed under a general anæsthetic, and the attic cavity carefully curetted. Very little relief followed in the

course of three weeks, the attacks of earache became more severe, and there was some slight pain over the mastoid.

Ten weeks after the ossiculectomy the radical operation was performed, and the attic, tympanum and antrum thrown into one cavity. There were a few granulations in the antrum and a very small quantity of muco-pus. The bone of the mastoid was extremely dense. The external wound healed by first intention, and in a fortnight's time skin-grafting by BALLANCE'S method was advised but the patient declined taking an anæsthetic again. It was decided to try the implantation of small epithelial grafts from the patient's arm, upon the granulating surface of the tympano-attico-antral cavities. The latter were cleansed by a warm saline solution, dried, and then three or four small grafts were applied and kept in position by a tightly packed strip of iodoform gauze, which was left in position for three days.

Additional grafts were then applied until nine or ten had been placed in position.

The majority of these grew without any difficulty, so that eventually (in three or four weeks) the greater part of the internal wound had covered over. The tympanic cavity still secreted a little moisture, but with care it would probably cease. The method was brought forward to illustrate that by this mode of grafting we might be able to expedite the cure of the discharge when, as in this instance, the patient would not consent to a second operation necessitating a general anæsthetic.

Mr. BALLANCE said Dr. TILLEY had done this operation by means of small epithelial grafts instead of using a second anæsthetic. He, Mr. BALLANCE, did not think the question of a second anæsthetic should enter into the decision. There was a crescentic perforation, and the position of the membrane which stretched across that was in the situation of the normal membrana tympani, so that the scar tissue membrane had grown up with a large perforation in the position of the normal membrana tympani, from beneath which discharge exuded. He did not think

the tympanum, or the attic, nor possibly a portion of the antrum, had taken the graft. Perhaps the fault was not Dr. TILLEY'S, as the patient may have gone away from his care before the completion of the treatment. He thought Dr. TILLEY had not removed all the soft parts from the tympanum at the first operation. In doing the radical mastoid operation every trace of soft tissue should be removed; if not, the present condition of affairs was very likely to happen.

Dr. TILLEY said it was 2½ months since he saw the patient until that evening. The only inconvenience experienced by the patient was a small point of moisture appearing every day at the opening of the Eustachian tube. He considered himself practically well.

In reply to Mr. BALLANCE, exactly what he had described took place. He, Dr. TILLEY, put on a certain number of grafts, and the patient then said he must get back to business. The condition seemed so satisfactory that he thought it would go on to cure. With regard to removal of all the soft parts, he had no hesitation in saying that this was completely effected. He brought forward the case as an illustration of the possibility of an alternative course to a second complete operation where the patient could not make up his mind for that, or where it was difficult to carry it out, for instance in the country. He would like to hear whether other members who might have tried the plan had had more success. He thought the patient might be considered to be out of any danger. He mopped up the moisture about once in two days, and considered the condition a trifling matter. He did not bring the case forward in opposition to the operation by means of a larger graft which Mr. BALLANCE had introduced, because no one would hesitate to adopt the larger graft where the patient would consent; but under the circumstances he had mentioned it might be an alternative.

Mr. BALLANCE said, as he had criticised Dr. TILLEY'S case, it was only right to say that in past years he had seen similar results when the patient went away from one's care. Both

with the old method of grafting and with the new, personal attention was absolutely essential to cure. If the operation were done in the country and left for a month or two months, however skilful the operator might be, the result would be disappointing. The patient must be seen frequently.

Case of sarcoma, probably primary, of Eustachian tube.

By F. C. Abbott.

W. M., *æt.* 19.—An engineer by employment. There was nothing of importance in his family or previous history, and no history of syphilis.

Three months before he came under notice he first discovered that he was deaf in his right ear.

This deafness increased and was accompanied by headache. Three weeks later enlarged and tender glands were noticed in the parotid region and in the upper part of posterior triangle of the neck.

These glands increased in size, and difficulty in opening his mouth commenced and increased. He found his nose often blocked, especially the right nostril, the secretion passing backwards into his pharynx. There was slight bleeding recurring at intervals from the nose.

The pain increased in the right side of his neck and throat.

He has deteriorated in health, become anæmic, and lost 22 lb. weight in the three months.

When seen.—There was great diminution in hearing power in the right ear, a watch being heard only at a distance of not more than two inches. Hearing on left side normal.

There was extreme retraction of right membrane tympani; nothing else abnormal through speculum; no passage of air at all along Eustachian tube.

There were a number of enlarged, hard but elastic glands in the right posterior triangle, beneath the upper two inches of sterno-mastoid, and in the pre-auricular region.

Some of the upper cervical glands on the left side were also enlarged and tender.

There was such great difficulty in opening the mouth that only liquid food could be taken; and as the little finger could with difficulty be introduced, an anæsthetic was given and the mouth forced open with a gag.

The right side of the soft palate was then seen to be much bulged down by a growth behind it, and did not move.

By the finger a smooth elastic half ovoid growth was felt in right side of naso-pharynx at base of skull. Its long axis was exactly in the line of the Eustachian tube, the lower and inner side of which it replaced. The mouth of the Eustachian tube could be felt at the anterior end of its long axis.

The growth appeared to be a sarcoma, growing from the periosteum or perichondrium of the Eustachian tube.

It was not ulcerated as far as could be felt by the finger. No view could be obtained of the tumour.

Operation was felt to be out of the question.

From the shape and position of the tumour I look on the case as one of primary periosteal or perichondrial sarcoma of the Eustachian tube, gradually, as it grew, occupying the whole length of the tube, and completely obliterating it.

The President said he once saw a lady with a very much similar condition. The onset was very rapid, death occurring only six weeks after the onset of symptoms.

Mr. Cheatle said it would be interesting to know whether pure Eustachian obstruction caused changes in the lining membrane of the middle ear. If the ear was not interfered with by growth it would be interesting to remove the middle ear, and see if any changes had been caused in the lining membrane. Sections of the other side might be cut to contrast with those from the diseased side.

Note.—Efforts have been made to follow up this patient. He was seen by Mr. Abbott three months later; was then weaker and more emaciated, and had glands in large masses down the right side of his neck, while those on the left side were also much more enlarged.

An operation had been attempted by another surgeon, but abandoned after removal of one of the pre-auricular infected glands.

The further history cannot be traced.

Mr. Ballance demonstrated a new portable motor for surgical purposes, especially for operations on the mastoid region, which was the result of the joint labours of himself and Dr. Milligan. The stand is made so that the motor will be at a convenient height and have a firm base of support. It is of about one-twelfth horse-power, and runs quietly and steadily. The speed can be regulated by a foot arrangement. The hand-piece is attached to a flexible steel arm, and both are nickel-plated. Simplicity is the great point aimed at. The hand-piece is detachable. There is scarcely any vibration, and patients are rarely sick after the burr operation.

FIG. 1.

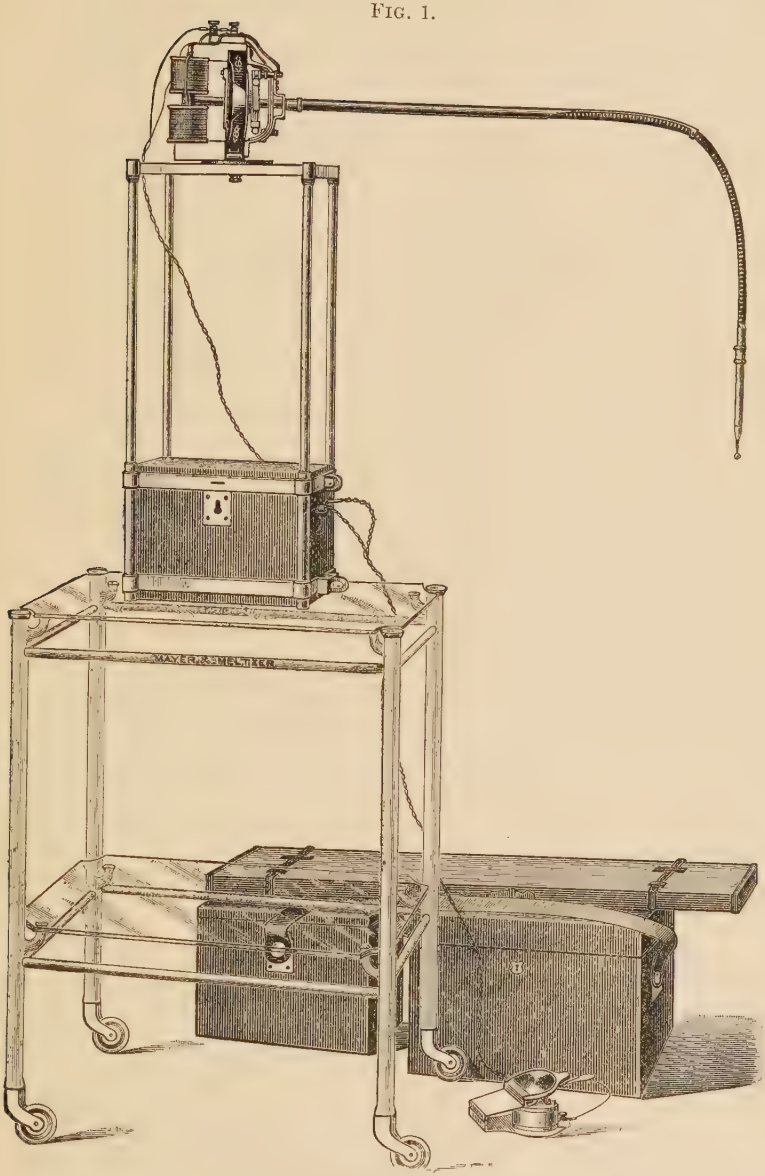

An electrical motor.
Mr. C. A. BALLANCE and Dr. WILLIAM MILLIGAN.

FOURTH ORDINARY MEETING.

MONDAY, *February 4th*, 1901.

THE PRESIDENT, SIR WILLIAM DALBY, IN THE CHAIR.

The PRESIDENT moved, and it was carried unanimously, the Members standing, that the following Address be sent to the King:

"MAY IT PLEASE YOUR MAJESTY.

"We, the President and Members of the Otological Society of the United Kingdom in Meeting assembled this day, beg dutifully and humbly to offer to his Majesty King Edward VII. and to the other members of the Royal Family their profound and heartfelt sympathy on the occasion of the death of our beloved Queen Victoria, and to assure his Majesty of their feelings of loyalty and devotion to his Throne and Person."

The following Gentlemen were nominated for election:

Charles Heath, F.R.C.S., 3 Cavendish Place, W.

Robert Fullerton, M.D., C.M. (Ed.), 24 Newton Place, Glasgow.

Frederick Westmacott, F.R.C.S., 8 St. John Street, Manchester.

(1) *A case of cholesteatoma treated by the radical mastoid operation, with preservation of the lining membrane and Körner's plastic flap.*

(2) *A case of cholesteatoma treated by the radical mastoid operation, with preservation of the lining membrane and Körner's plastic flap, with resection of cartilage.*

By Dundas Grant.

The first was the case of an elderly woman who, on account of severe cerebral symptoms occurring after several years suppuration, was operated upon by the radical method. A large cavity of cholesteatomatous nature was found. He scraped away the contents of the cholesteatoma without removing the lining membrane. He then made a large meatus by Körner's method. He removed the cartilage so as to overcome the resiliency of the flap which he intended to turn backwards, and retained it in position by means of plugging. He hoped that the lining of the cholesteatoma would serve as a fair substitute for the pseudo-epidermic lining which they endeavoured to procure. The operation was done about six weeks previously. The result as regards the meatus was extremely good, but, unfortunately, the plugging was not carried out in the hospital, as she would not stay. As a result, the soft parts of the meatus had not adhered to the walls, but had joined together, so that there was now only a very narrow opening left at the deepest part. The external portion of the meatus was extremely large, but there was a diaphragm forming, so that the result was not yet so satisfactory as he hoped it would be. He would be glad to hear from the members what was the best to be done.

The other case was entirely satisfactory. It was that of a boy twelve years of age who had chronic suppuration of six or seven years standing. He was sent up from the country on account of severe cerebral symptoms. On performing the radical mastoid operation Dr. GRANT found it was a case of cholesteatoma. In this case he scraped out the contents without removing the lining, made a Körner's flap extending a little distance into the concha, and, in order to overcome the resiliency, stitched the flap back, after the method recommended by Mr. BALLANCE. The result was entirely satisfactory. The flap took root, and the lining of the cholesteatomatous cavity seemed to form a sort of substitute for the Thiersch's graft which they had so much admired in Mr. BALLANCE'S cases. He had not seen the boy since last March, but he was under his observation for a fortnight after the operation, and his doctor wrote to say the discharge had ceased. On questioning the boy's mother it appeared that the discharge came to an end a month after the operation.

Dr. W. HILL said he would not feel satisfied with the result in the boy's case, as there was a mass of crusts and *débris* in the cavity. He generally put in peroxide of hydrogen to see if it bubbled; it nearly always did in such cases.

Mr. C. BABER said he had a case a few months ago in which he did the radical operation. The patient was a woman of fifty, and he intended to transplant, but it epithelialised over without giving him a chance, and in five weeks it was dry. Since then there had been desquamation and it had not been perfectly dry. Thus it seemed to him that in some cases transplanting was not necessary

Dr. MCBRIDE said he thought Dr. GRANT'S idea of making the cholesteatomatous membrane serve the purpose of a graft was a wrong one. He understood the pathology of cholesteatoma to be that the membrane threw off masses which eventually formed the tumour. If that were left it would be the material from which recurrence would occur. Indeed, he believed recurrence was already setting in in the posterior and upper part.

Dr. URBAN PRITCHARD thought it was important to destroy the membrane as much as possible, and he had always mopped out with strong carbolic acid, of viscid consistency. The membrane was very thin and the bone very hard; in fact, by feeling one could tell it was cholesteatoma *versus* ordinary mastoid disease. It was dangerous to leave the membrane in the hope that it would form a healthy membrane. He would watch the case with interest. In the case of the woman, it was evident that the hole wanted opening up again and treating in a more radical manner; but he thought there would be considerable difficulty in preventing it from growing over again.

Mr. BALLANCE said, with regard to the boy, that he thought a small cholesteatoma was forming at the lower part of the tympanum, which probably had beneath it a granulation. They could not tell anything about the case unless the parts were properly cleaned out. He thought the woman ought to be operated upon at once, as there was obviously a small opening into a large cavity which was secreting pus, and he believed another cholesteatoma was forming there. The tympanum was not exposed, the flap had adhered across about the middle of the osseous meatus, and he thought the tympanic and antral cavities were some distance from the flap. Behind was obviously a large cavity, which might contain all sorts of horrible materials. With regard to the pathology of cholesteatoma, from what they knew it was not at all good practice to leave a portion of it behind, and that was especially laid stress upon in the paper by Siebenmann. It was wrong in pathology and in surgery to leave behind disease which could be easily removed.

Dr. GRANT, in reply, said he pointed out, in regard to the first case, that he did not consider that the after-treatment had been sufficiently carried out, and therefore asked them not to form any judgment in regard to principle based on that case. He proposed to slit up the diaphragm, which was not a great distance from the inner wall of the tympanum, and see that proper plugging was carried out. Despite the opposite views which had been expressed, he

hoped that the case would recover perfectly well. He had seen similar adhesions between soft parts take place and yield to similar treatment. The boy's ear had not secreted a single drop of pus since a month after he left his care, which was in April of last year. With regard to the danger of leaving cholesteatomatous membrane, he certainly agreed it should not be left in the geographical position in which it originally was; but it made all the difference in the world where they had the lining, whether it was in a bottle-shaped cavity, where it could persist as long as there was moisture secreting, like the skin in the umbilicus of a fat person, or whether it was spread out and exposed to the air. Part of the treatment was to make as large an opening as possible for the entrance of air, and it was with that view that he made such a large meatus in the woman's case. So far as the plastic layer there was concerned, he thought it had served its purpose extremely well. As to the pathology of cholesteatoma, if they took the view that it was desquamative dermatitis, the first step was the invasion of epithelium from the skin through the orifice in the membrane to the mucous membrane, converting that membrane into a kind of cutis, which was, like the rest of the cuticle, a desquamating surface, but, being exposed to the air, the skin did not collect. He did not think there was anything essentially malignant, in the pathological or clinical sense, about the lining membrane of a cholesteatoma. When, in the old way, a cavity in the middle ear was allowed to heal up after operation, it was by the extension of ephithelium over the granulating surface. His principle was that they had that epithelium already formed, and they should preserve it and make the most of it. He hoped the principle would not be lost sight of.

Severe aural vertigo treated by operation. Cure.

By H. Macnaughton-Jones

The patient, aged 62, suffered diminution of hearing from childhood. This he traced to an attack of otitis which

followed measles, when there had been a discharge from the ears. This ceased in the right ear, but continued for some time in the left, from which, as far back as 1872, a polypus was removed. Again there was some chronic discharge. In 1887 he consulted a distinguished physician for recurrent attacks of vomiting and giddiness. His ear was examined, and it was found that there was re-growth of the polypus. He remained under able aural treatment for nine years, being operated upon on several occasions for recurrent growths. Occasionally he was troubled with severe tinnitus. In April 1898 he was again attacked with severe vomiting, attended by migraine. The sensation he described as "the floor of the room coming up, and the ceiling going down." On rapidly turning a corner, somewhat the same symptoms occurred. There were some associated visual disturbances, as, for example, seeing white and blue stripes, something, as he said, like those on a flannel shirt. If he looked at his dressing-gown, which was striped, he immediately became giddy, and as he lay in bed the room occasionally appeared to move round. Of late these attacks had become worse, the sickness more incessant, and he had to live principally on milk and soft food. He complained of some pain, radiating over the left side of the head, and he also had attacks of general headache. He next consulted two distinguished neurologists. One advised a cranial operation, the other did not give an opinion as to its advisability, and said little save that he thought that he might undergo it. This was at the end of 1898. On the 20th of the previous December he had had a very bad attack in a public lavatory, where he had become unconscious and had to remain in it for an hour and half before he could be removed. When seen his general condition was as follows: He was led into the room requiring to be supported. He could not stand with his eyes closed, with his legs together, or with one leg raised. His gait was uncertain; he had rather a livid look; there were dilated veins on his face; his pulse was sixty, feeble, and intermittent. The cardiac area of dulness was increased, the rhythm irregular, and the first sound feeble. There was considerable abdominal fulness,

with hepatic enlargement. On examining the right ear absolute deafness was found to Galton's whistle and to conduction with the tuning fork, but there was nothing special to remark about it further than that the tympanic membrane presented the usual appearance seen in old cases of sclerosis. In the left ear a new membrane had formed, which covered in the tympanum. On testing his vision a high compound presbyopic astigmatism was discovered, which could be fairly corrected both for distance and reading by suitable lenses.

His last attack of vertigo occurred on the 23rd of January, 1899, at 7 A.M., and he had counted from the bad attack in April 1889, as many as twenty seizures of severe vertigo. It was decided that any cranial operation would, in his condition, be attended by the greatest risk. There was little doubt that the principal cause of his giddiness and migraine was to be found in some intra-tympanic growth. Still, it was thought that the associated and uncorrected astigmatism might also play a part in its causation. It was therefore advised that in the first instance the tympanum should be attacked from the meatus, its cavity opened, and any growth found there removed. This was done under ether and oxygen on the 30th of January, 1899. The membranous covering was removed completely, and behind it a mass of granulation tissue was found and thoroughly curetted away. The bare cavity, when cleansed and dried, was filled with iodoform gauze. The patient gave the anæsthetist (Mr. BAKEWELL) rather an anxious time during the operation, and on the first occasion of removing the iodoform dressing he had an alarming attack of syncope with collapse, so much so that a subcutaneous injection of strychnine, and an inhalation of nitrate of amyl were found necessary. There was a recurrence of this symptom on another occasion of dressing. He left the Home in which he was operated upon on the 12th of February 1899, and on the 29th of April he wrote a note saying: "I now tricycle from four to seven miles; have completely lost my giddiness; have a good appetite, and can eat anything."

Before this his astigmatism had been corrected for distance and near work. Up to a few months since, he has been

under observation, with his own medical adviser, who was present at the operation. On a few occasions there was a tendency to re-appearance of some granulations. These were treated with tri-chloracetic acid. He greatly improved in general health and appearance under treatment for his cardiac condition, has been occupying an important public position, and acted for a year as President of a large public association. For all practical purposes his hearing is good.

For some time he suffered from gouty inflammation of the meatus of both ears, but when last seen he had not had a single attack of vertigo or vomiting since the operation. Lately his general health had not been so good as it was.

A patient upon whom the radical mastoid operation has been performed for chronic suppurative disease of the epitympanum and adjoining mastoid cells.

By W. Milligan.

The patient, a male aged 38, had suffered for many years from suppurative middle ear disease upon both sides, with gradually increasing deafness. The discharge was always fœtid and was occasionally blood stained. Latterly he had suffered a good deal from headache, especially upon the left side. Constant tinnitus upon the left side of the head kept him awake at night. His general health was poor, the least exertion causing undue fatigue. When first seen, in March 1898, both membranes were found perforated, the perforations being situated in the anterior parts of Shrapnell's membrane. A foul discharge was oozing from the epitympanic cavities. Tufts of granulation tissue were seen protruding through the perforations. With a small curved probe carious bone was easily detected upon both sides. Upon the right side the hearing power was $\frac{2}{80}$, and upon the left the watch was just heard on pressure. Tuning fork tests showed both nerves to be healthy.

For a few weeks antiseptic treatment was used, the epitympanic cavities being at the same time washed out with

an intra-tympanic syringe. Upon April 5th, 1898, under ether narcosis, the granulation tissue was removed and the accessible carious bone curetted. Antiseptic treatment was again resorted to, a fine strip of carbolised wick being passed right into the attic and changed daily. The result of this treatment was that, by the middle of June, the right ear was healed and the hearing power slightly improved. The left ear, however, continued to discharge much as before, the discharge continuing to be extremely fœtid. For six months antiseptic treatment was continued, but without much result.

The patient was again put under an anæsthetic, and this time the ossicles and outer attic wall were removed and adjoining parts curetted. The effect was to arrest suppuration for nearly twelve months. At the end of this time the patient again began to complain of a recurrence of discharge from the ear, of occasional pain in the head, of slight vertigo and of general mental hebetude. Upon examination pus was seen oozing from the left epi-tympanic region, and with a bent probe bare bone could be detected extending towards the mastoid region.

A radical operation was advised, and was performed upon May 22nd, 1900. Upon May 31st, a grafting operation was performed, a graft being taken from the patient's left thigh. At the end of the fourth week following the grafting operation, the parts were found quite dry and soundly healed. Since then the patient has remained well and expresses himself as being quite able to conduct his large business. A noteworthy feature in the case is the remarkable improvement in his capacity for hearing ordinary conversation, especially with his left ear.

The President said the case was so excellent in its result that it left little to be desired.

Cholesteatoma of mastoid. Radical cure.

By P. de Santi.

Harry J., *æt.* 23, had suffered from a discharge from the eft ear for twenty-two years. It had never to his knowledge ceased. He was in a hospital ten years ago, and had an operation performed on his left mastoid, but without benefit to the discharge.

When seen in July 1900, he was suffering from very severe frontal and occipital headache. He was frequently sick, especially after food. He had very severe vertigo, and had been sleepless for several nights. He looked ill, his bowels were constipated and his temperature 102° F. He had a rapid pulse. There were no eye symptoms present.

Examination revealed a large perforation in the left tympanic membrane, a discharge of pus and shiny epithelial *débris*, and a sinus at the back of the left ear leading into the mastoid antrum. With a small scoop, cholesteatomatous matter was extracted.

The region of the mastoid antrum was very prominent.

The patient was operated on the day after admission, following up the post-auricular sinus. The mastoid antrum was very much expanded and contained a large and typical cholesteatoma. This was thoroughly removed and attico-antrectomy performed. The wound was packed with iodoform gauze and allowed to heal up from the bottom.

All discharge from the external auditory meatus had ceased by the end of September, and the large post-auricular wound was dry by November, and has remained so since.

His hearing was $\frac{O}{C}$ W before, and is the same since operation.

This patient presented the usual symptoms of a cholesteatoma, and I bring the case forward to ascertain the views of Members of the Society as to the treatment of the large post-auricular wound. I personally propose to close it by a plastic operation.

In both the cases brought forward Mr. DE SANTI thought he might have adopted Mr. BALLANCE'S recent operation for filling up the cavities with skin grafts, but he ventured to think that both cases have done very well, and should remain well, under the simpler methods.

Mastoid abscess: extensive gangrenous emphysema of scalp tissues. Attico-antrectomy. Cure.

By P. DE SANTI.

William S., *æt.* 17, was admitted into the Westminster Hospital on November 14th, 1900. He attended the Aural Out-patient Department the day before with the following history:

He had suffered from a continuous discharge of yellowish matter from the right ear for eight years. He had been under treatment occasionally, and some six years ago a small post-auricular abscess had been opened by my predecessor, Mr. BLACK. The abscess was opened in the Out-patient Department, and could not therefore have been a condition of any gravity.

He had been deaf, especially lately, for nine years in the right ear.

On examining the patient the membrana tympani was found entirely destroyed and there were no signs of the ossicles. There was a thick foul-smelling discharge from the right ear; no caries or necrosis to be detected.

Watch $\frac{\text{O}}{\text{Contact}}$.

The whole of the right auricle was stuck prominently forwards and outwards by a very large swelling occupying the whole of the mastoid region, and extending forwards to the outer angle of the orbit, upwards to the sagittal suture, backwards to the lambdoid suture, and downwards into the cervical region to the level of the hyoid bone. The swelling, especially round the mastoid region, gave the feeling of pus. There was a temperature of 101° F., and the patient

had a dull, stupid expression. There were signs of old adenoid growths. There was pain on pressure over the mastoid and parietal regions, but no redness of the skin. He had had severe pains in the mastoid and parietal region of the right side for two to three days, and the swelling was stated to be of the same duration. He was suffering from very marked vertigo and a staggering gait. He had had no sickness or drowsiness; on the contrary, there had been sleeplessness. The fundus oculi was normal, and there was no evidence of pain in the line of the internal jugular.

On November 14th the patient was put under an anæsthetic, and a very free incision was made over the mastoid process, extending well forward to the top of the auricle. A large amount of putrefactive gas, instead of pus, at once escaped from the tissues. The stench was very great. The mastoid process was found to be bare, and there was a small sinus surrounded by black necrotic bone opening into the antrum. The deep soft structures lying over and beyond this area were black and gangrenous. The mastoid antrum and cells were opened by means of gouges and a large amount of very fœtid pus and epithelial *débris* was removed. The mastoid antrum was much distended. The whole of the antrum attic and middle ear were then thrown into one by the usual operation, the gangrenous soft tissues cut away, the whole of the parts swabbed out with pure carbolic, and the bone cavities stuffed with dry iodoform gauze. The skin wound was partly closed.

The dressings were changed daily, and the patient made an uneventful recovery.

The extensive swelling of the scalp tissues disappeared within four to five days, and by January 15th the whole of the wound had healed and all discharge from the ear had ceased. The patient remains well, and his hearing to a watch has improved from $\frac{O}{C}$ to $\frac{2-3}{36}$.

The interest of this case lay in the extensive subcutaneous gangrenous emphysema and the patient's general condition on admission, also the rapidity with which recovery ensued.

Dr. GRANT thought the first case was of interest with regard to cholesteatoma. It was stated that a fistula was left behind the ear at the first operation, and he thought it was probably a case of what had been called artificial cholesteatoma, and that there was an epidermis-lined cavity. It was one of the drawbacks of the Schwartze operation that this was likely to take place. He believed it occurred in other parts of the body in connection with mucous-lined viscera. In the present case it would be difficult to deal with that cavity behind the ear. He supposed desquamation would take place into it, and that it would have to be cleared out from time to time. No doubt by a plastic operation it could be closed up, but the meatus was so small that it would be of little service for the purpose. Probably some form of operation, such as Ballance's or Körner's, might be adopted, so as to throw the meatus into one cavity behind the ear.

A patient on whom ossiculectomy had been performed for perforation and cholesteatomatous formation in Shrapnell's membrane.

By ST. CLAIR THOMSON.

This patient was first shown at the meeting of March 1900 (*vide* Trans., vol. i. p. 43). The malleus and incus, which were shown to the meeting, were removed in April last. As a consequence the patient had entirely lost the fœtid discharge from the ear and the hearing had improved. The watch was still inaudible, as it was before; but the whisper, which was previously unheard, could now be recognised at a distance of 2 inches, while the hearing for loud speech had gone up from 2 feet to 6 feet. On inspection it would be seen that the inner tympanic wall was covered with a thin cicatrix. In the lower segment of this was a small perforation through which moisture still oozed. Dr. THOMSON asked if this perforation and moisture were frequently met with after ossiculectomy. The secretion was so slight that the patient was with difficulty persuaded to

syringe once a week for cleanliness. The outer attic wall had not been removed.

The PRESIDENT said he remembered the case, and certainly the condition seemed to have been relieved since it was last shown.

Dr. MCBRIDE said it seemed to him that there was not only a lot of fluid, but that it exhibited distinct pulsation at the point. He did not see the patient previously, but thought he was not yet past recurrence.

Mr. YEARSLEY said he had certainly noticed the formation of cicatrices. He thought the attic wall ought to be removed before one could hope to get a perfect result.

Dr. W. HILL asked whether it was an ordinary mucous secretion of the tympanum, or whether it was pus.

Dr. ST. CLAIR THOMSON said he did not present the case as one of complete cure. In March last he put three alternatives before the members: (1) radical operation at once; (2) ossiculectomy; (3) leaving it alone. Ossiculectomy was therefore done as a first step. The man was not inclined to keep his ear clean, because he said there was no fœtor. He had encouraged him to keep it clean by syringing. He had not seen him since the early part of December. He had the opinion that the discharge was purely mucous, and that it came out of the little perforation in the cicatrix. He had told the man to report himself from time to time. If further treatment were required, would Mr. CHEATLE recommend attempting to remove the outer attic wall by the meatus, or approaching through the antrum? The man said he would be able to get along with that ear if he were to lose the other.

Mr. CHEATLE, in reply, said he would not hesitate to open it from behind; he would do a complete post-aural operation.

Case of injury to the labyrinth.

By P. Macleod Yearsley.

This man, *æt.* 44 years, was run over by a cart on January 3rd, 1901, the wheel going over the left side of his head and over the ear of that side. He was taken to St. Mary's Hospital, where he remained for three days. The left ear bled. He was first seen January 16th, when he said that ever since the accident he had been deaf in the left ear, with hissing and booming tinnitus. There was much vertigo, and it was noticed that he could not walk straight across the consulting-room but lurched to the left. He stated that he had frequent fits of vertigo, with a tendency to fall forwards, and that external objects appeared to move from left to right.

The hearing in the right ear had long been dull, and he had had a foul discharge from that ear on and off for many years, but this had not recurred since July 1900.

He could not hear the watch or acoumeter with either ear. The tuning-fork held on the vertex was referred to the right ear. The bone conduction was impaired on both sides, but the loss was much greater on the left side, over two-thirds being lost.

On examination, the right membrana tympani was found to be the seat of an anterior perforation, but there was no pus.

The left membrane presented a thick, pink, fleshy-looking triangular cicatrix.

He was ordered half-drachm doses of dilute hydrobromic acid three times a day, his tinnitus and vertigo being a source of considerable trouble to him.

On January 23rd he stated that he was better. He was much improved by his ability to obtain better rest at night. The vertigo was much less and he had therefore more confidence in himself. The tinnitus was less loud and less persistent, and was now only hissing in character.

The hydrobromic acid was increased to drachm doses three times a day.

It was intended to carefully examine his tuning-fork reactions with Hartmann's series, but he did not keep his appointment.

A case of acute temporal bone septicæmia.

By Charles A. Ballance.

Mr. G., *æt.* 24, came under observation after five days of acute illness with high temperature, quick pulse, and rigors.

Previous History.—Scarlet fever at age of 7 years. Right otorrhœa ever since.

October 2nd, 1900.—*Operation.*—The mastoid operation was performed.

October 4th, 1900.—The sinus, which did not contain clot, was opened and plugged, and the jugular vein was tied above the entrance of the facial trunk.

October 6th.—Operation.—The upper ligature on the vein was removed, and daily antiseptic irrigation from the opening in the sinus through the vein to the wound in the neck was commenced.

October 7th and 8th.—Patient was in a cataleptic state.

October 13th.—Some thin pus was evacuated by means of a bent probe from the posterior surface of the petrous.

October 14th.—Operation.—An incision was made into a brawny swelling of the right side of the neck below the operation region which had rapidly matured during the preceding two days. No abscess was opened, but the cellular tissue was grey, œdematous, and gangrenous.

October 19th.—Patient died.

The main features of the case were:

(1) The frequent rigors (*see* Chart of Temperature, page 38).

(2) The extreme foulness of the wound in the temporal bone, which no treatment seemed to modify. The local gangrenous condition of the bone spread later to the soft parts.

(3) There was no optic neuritis, no headache, no vomiting,

Fig. 2.

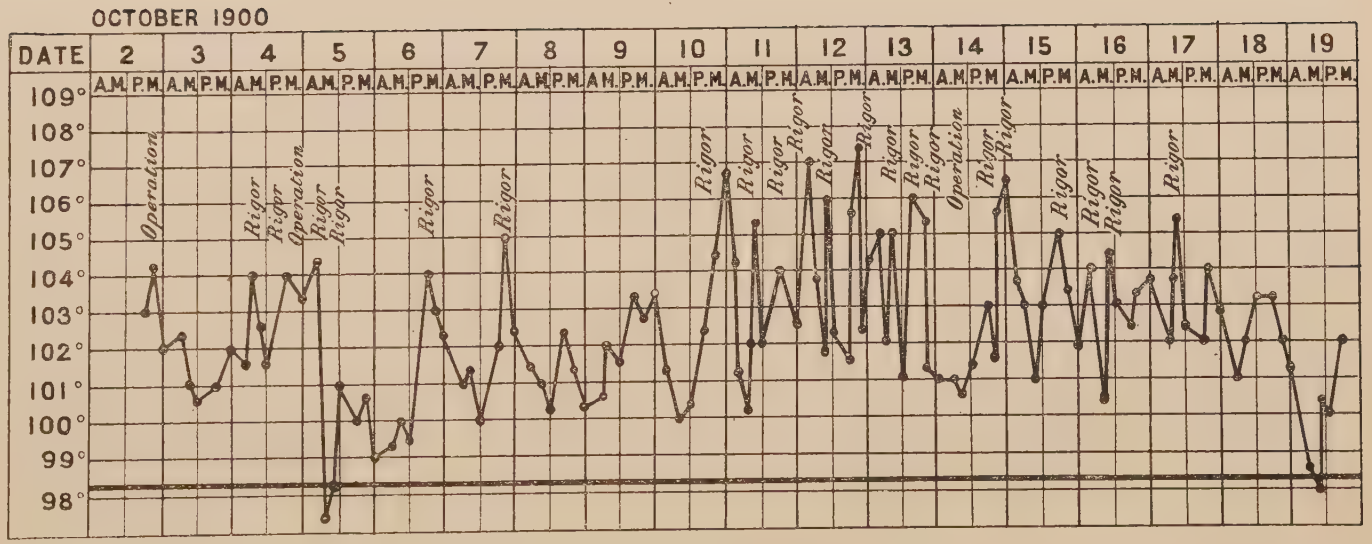

Case of temporal bone septicæmia.
Mr. C. A. Ballance's Case.

and the mind remained clear till within twenty-four hours of death.

Autopsy.—Bone around area of operation necrosed, black and foul. Torcular end of wound in sinus plugged by non-septic clot. No secondary abscess anywhere.

The case is an example of acute fatal septicæmia from suppuration of the temporal bone, such as is occasionally met with in surgery in consequence of purulent infection of the cancellous tissue in a bone wound.

Microscopic section of epithelioma of cutaneous external meatus which was at first mistaken for mastoid disease.

By Adolph Bronner.

During the last few years several cases of epithelioma of the external auditory meatus have come under Dr. Bronner's notice, which at first presented rather misleading symptoms.

The following is a very typical case.

Mrs. G., *æt.* 60, was seen in February 1896. She had been deaf in the left ear for three or four years and had noticed a discharge from the ear for over one year. During the last four months she had had severe pains in the ear, which extended on to the cheek, temple, and below the ear. The ear had been painful on pressure for a few weeks. There was extensive swelling of the meatus; on incision a very little pus escaped and there was severe hæmorrhage. Glycerine of carbolic acid ear drops and hot fomentations was ordered. The patient was seen again in October 1896. After the incision there had been less pain for a few weeks, but latterly the pain has been very severe and has also extended backwards and upwards. The meatus was quite closed. The mastoid process was painful on pressure and distinctly œdematous and swollen, and there was apparent fluctuation; on incision no pus escaped. The thickened skin of the meatus was examined microscopically: it was a squamous-celled epithelioma without cell-nests. The greater part of the ear, the external meatus and surrounding parts

were removed; the upper part of the external ear, which was not removed, was stitched across the wound. In a few weeks the wound had healed and there was very little deformity. The patient was last heard of eight months ago, and there had been no recurrence.

These cases are fairly common and often overlooked. It is of great importance that they should be recognised and operated on as early as possible.

The symptoms at first were those of furunculosis of the external meatus, and later on were very like those of mastoid abscess.

If possible, we should try and preserve part of the external ear if it is not extensively affected, so as to avoid subsequent deformity. A person without an ear looks rather ghastly, and if but a small portion of the auricle can be preserved the disfigurement is only very slight.

The President said that he understood Dr. Bronner to say he saw a good many that began in the skin.

Dr. Bronner replied that he had, internally, but there was no apparent growth outside.

Mr. Ballance asked how many Dr. Bronner had seen commencing in the meatus. Also whether there was any suppuration or other trouble in the ear.

Dr. Bronner: Five or six in the last few years. He had operated on three of them, and they have done very well, and there has been no recurrence. Nearly all suppurated.

Dr. Macnaughton-Jones said that was an unique experience, as he always understood that epithelioma of the external ear, in comparison with other affections of the external ear, was very rare. It would be worth while having the particulars of those cases to put on record.

The President said he was surprised to hear that the cases were so common. He had seen a good many instances of malignant disease of the ear, but, with one exception, they all arose from the tympanic cavity. In the one exception it arose from the skin at the back of the mastoid. That was the only case of its kind he had ever seen.

Mr. CHEATLE said he showed one case, on which he had operated, to the Society, and that was the only one he had seen.

Dr. TILLEY asked Dr. BRONNER whether, in the five or six cases he mentioned, hæmorrhage had been a common symptom in all of them. At present he had the case of a woman 55 years of age, who looked older than her years, and in whom the least touch on the granulation produced profuse hæmorrhage, and there was lancinating pain through the head. The mastoid was tender to pressure. She was so poorly that he advised her to have her general health improved before he would attempt an exploratory incision.

Dr. URBAN PRITCHARD said he had not seen half a dozen cases, in over twenty-five years experience, of epithelioma commencing in the skin of the meatus. In two of them the whole of the auricle was removed, and both those cases lived a considerable time. One was alive seven years afterwards, and died from something else, and the other was lost sight of four years afterwards. That caused him to remember a case in which he did not shine—and it was well to confess one's sins and mistakes. One day a surgeon brought a case to him for an opinion. He (Dr. PRITCHARD) had then a habit of jumping to a conclusion and then trying to verify it afterwards. He pronounced it to be epithelioma. The surgeon who brought it said he had tried mercurial treatment. It was agreed to remove a piece and have it examined. This was done, and the opinion was confirmed. Complete removal was decided upon, and the surgeon was chosen, but the day before the patient "funked" the operation. A year afterwards the case was encountered perfectly well. He had been to see a shrewd general practitioner, who had given him mercurial treatment, and he recovered.

A specimen and microscopical section of a case of tuberculosis of the middle ear lining membrane from an infant.

By Arthur H. Cheatle.

The specimen was taken from an infant who had died of general tuberculosis. A perforation was present in the posterior segment of the membrane through which could be seen the lining membrane in a thickened and nodular condition. The middle ear, including the antrum, was full of cheesy pus. Sections of the lining membrane, stripped off the horizontal semicircular canal, showed general small-celled infiltration with numerous caseating areas, giant cells. and tubercle bacilli scattered through.

The question was asked what should be the treatment if the condition was recognised during life?

Attention was drawn to the fact that the antrum shared in the disease. Mr. Cheatle stated that, as far as his examination of post-mortem specimens went, he had come to the conclusion that any inflammation attacking the lower middle ear was always shared by the attic and antrum.

A specimen of a gap in the handle of the malleus, probably congenital.

By Arthur H. Cheatle.

The specimen was obtained from a young male adult who had never suffered from disease of, or injury to, the ear.

The handle of the malleus, immediately below the attachment of the tensor tympani, ended abruptly, and, separated from the stump by a distinct interval, was the tip of the handle represented by a small nodule of bone.

The membrana tympani was intact and there were no signs of disease.

Fig. 3.

Tuberculosis of the tympanic lining membrane.

Mr Arthur H. Cheatle's Case.

Bullet wound through brain and cerebellum, leaving no after effects beyond loss of hearing on one side.

By Sir William Dalby.

On January 6th, 1900, during the engagement at Wagon Hill, Lieutenant C. fell, being shot through the head with a Mauser bullet. He remained absolutely unconscious to evening of January 8th, and became semi-conscious on January 9th. From that date he gradually made a complete recovery, the only lesion remaining being absolute loss of hearing on left side.

After his return to England Sir William made an examination at the request of the military authorities, in order to make a report of his condition for the Medical Board.

The bullet entered at the right ala of the nose. Its exit was at a point $2\frac{3}{4}$ inches behind the top of the left mastoid. The Mauser bullet proceeds in a straight line through bone. If it passed over the internal auditory meatus it was truly remarkable that the facial was not paralysed. The patient was in perfect health with the exception of total loss of hearing on the left ear and a just perceptible slight tinnitus on the same side.

A fatal case of extra-dural abscess and cerebellar abscess.

By C. H. Fagge.

D. T., *æt.* 3 years, was admitted into the Evelina Hospital for Sick Children on September 14th, 1900.

She had had measles two years previously, followed by double otorrhœa; the discharge from the left ear had ceased some months before, and that from the right ear had diminished during the last week, since when the child had complained of pain in the right ear, and the scalp behind it had become swollen. Sleep was interfered with. No history of sickness.

Conditions on admission.—T. 102. P. 148. Respiration *circa* 30. Right side of scalp behind ear swollen, œdematous,

red and tender. Drowsy, but irritable if disturbed; much very foul pus flowing from right ear, left normal. Discs could not be seen. Child evidently very ill.

In the absence of Mr. ABBOTT, under whose care the case had been placed, Mr. FAGGE was asked to see the case with a view to immediate operation.

The symptoms suggested an acute mastoiditis, following a chronic suppurative otitis media. It was decided to operate at once.

Chloroform was given, and on making the usual crescentic incision over the right mastoid, a large amount of extremely offensive pus escaped from under the incised periosteum; the area of bone so exposed was noticed to be well behind and rather below the situation of the antrum in the supra-meatal triangle, which was now laid bare. The bone here appeared healthy, but the bone exposed under the abscess cavity was white and exuding pus from many small openings. This bone was soon gouged away over an area the size of a shilling, and most foul pus escaped from an extra-dural abscess over the supero-external limit of the right cerebellar lobe: the dura was beginning to slough, but there was no apparent perforation; the lateral sinus exposed in the upper limits of the wound was, to inspection and touch, normal.

The radical mastoid operation was then easily completed, rather too easily, for the bone seemed rotten in all directions. Great care was taken to avoid the Fallopian canal, and no twitching of the face was noticed. The wound was then swabbed over with pure formalin and loosely plugged with sterilised gauze both through the meatus and from behind.

After thirty-six hours, when dressed, there was no smell, and no pus on the dressings, but facial paralysis, noticed soon after the operation, was complete. The case progressed satisfactorily for six days, the temperature being below 100° and pulse 120–100, but on September 20th the pulse became irregular and slow and the temperature gradually fell.

	2 A.M.	6 A.M.	10 A.M.	6 P.M.
Pulse.	92	84	96	62

During the afternoon Mr. FAGGE found that at 5.45 she

had been sick, and that increasing drowsiness had, since about 6.15 P.M., developed into unconsciousness. The temperature was 97. Respiration 14 and irregular. Pulse 62.

There was advanced double optic neuritis. The patient was placed on the operating-table and a few whiffs of chloroform given, as the condition was obviously that of intracranial abscess. The wound was well opened up, the sloughy dura incised, and a director, followed by a pair of dressing forceps, pushed inwards and forwards into the cerebellum, caused about ℥ij of exceedingly foul pus to come away. The cerebellum immediately began to pulsate and bulged a good deal; much of the superficial cortex which was sloughing was removed, so that the abscess floor was well exposed; a rubber tube was inserted and the wound dressed as before, the pulse immediately becoming regular, at 88 per minute.

The child did exceedingly well for some days, was quite conscious; took notice and played with her toys. Temperature, pulse, and respiration were satisfactory. The discs were several times examined, and on one occasion Mr. SIDNEY STEPHENSON reported that the neuritis had nearly cleared up; but later still it was noticed that the child was wasting, she became more apathetic, was occasionally sick, and from time to time a clear fluid escaped from the granulating cerebellum (no doubt cerebro-spinal); on several occasions, when this fluid did not run away, she was more drowsy and more sick, and then collections were easily discovered in the gradually increasing hernia cerebelli and evacuated with dressing forceps. There was now no leucocytosis. Mr. ABBOTT agreed that, though the child was slowly dying, there was no indication for further operation.

She gradually failed and died on October 25th, forty-one days after the first and thirty-five days after the second operation.

All efforts failed to obtain permission for even a partial post mortem.

Mr. FAGGE regretted the following omissions in the report of the case.

(1) The absence of bacteriological examinations of pus from the middle ear, extra-dural abscess, and the cerebellar abscess.

(2) The absence of a post mortem; but he brought the case before the Society for the following reasons:

(*a*) The age of the child. A fairly extensive research into the literature of cerebellar abscesses has enabled me to find only three other cases under four; all of which are collected in Ballance's paper. (*St. Thos. Hosp. Reps.*, 1894.)

All those were fatal.

(*b*) The rapid onset of urgent symptoms of the cerebellar abscess.

(*c*) The escape of the cerebro-spinal fluid, which has not been found previously referred to in books or papers, but which has been previously noticed. This was taken to indicate leptomeningitis, and I especially ask for information as to its prognostic importance and treatment.

(*d*) The cause and treatment of the hernia cerebelli. The parallel instance of intra-cranial tumour does not always produce a hernia after trephining to relieve pressure. When and why does a hernia result?

In this and several other particulars, such as mode of death, Mr. MILLIGAN'S case, read last session, somewhat resembled his own. (*Otolog. Soc. Trans.*, vol. i.)

Mr. CHEATLE said the disease might be tuberculous. The occurrence of hernia cerebri touched him nearly at the same time, because he had such a case under his care at King's. It was nearly three and a half months since an abscess in the temporo-sphenoidal lobe was opened, and the hernia did not seem to get much larger. He had partly removed it several times, and when he had cut off pieces he had come across collections of pus in the hernia. He took it that it meant increased intracranial tension, and possibly another abscess.

Notes of a case of removal of an impacted meatal sequestrum facilitated by previous decalcification.

By URBAN PRITCHARD.

This case illustrated the value of decalcification, by dilute mineral acids, of sequestra of the osseous meatus, allowing of their early and easy removal even when a general anæsthetic was inadvisable. Dr. PRITCHARD had called attention to its value for removing sequestra from the ear in 1882 (*Brit. Med. Journ.*).

X. Y., *æt.* 75, a somewhat feeble old gentleman, sent to him first on April 30th, 1900, for a second opinion, and afterwards placed in his hands for removal of the sequestrum by Drs. MCBRIDE and MACLACHLAN.

April 30th. History of ear trouble.—Since October 1899, suffering from pain in left ear with stiffness of the jaw and discharge from the meatus, which was more or less profuse and fœtid.

Under Dr. MCBRIDE'S treatment the pain ceased and the discharge very much improved. Within the last few weeks there was return of pain, the discharge became more profuse and contained some minute gritty pieces of bone. Seen again by Dr. MCBRIDE, who discovered a sequestrum in the floor of the meatus. Discharge improved under instillations of solution of peroxide of hydrogen, followed by syringing and then instillation of alcohol and boric acid.

On examination a large sequestrum was found fixed and surrounded by swollen tissues, no granulations, very little non-offensive discharge. There was still some dull pain.

The following decalcifying injection was ordered:

Acid nit. pur. ʒij.
Aquæ ad ℥vij.
Glycer. acid. carbol. ℥j.

One part to two of warm water for syringing 3 times a day, = 1% of nitric acid.

The patient went north again; and for reasons of his own did not use the acid injection as ordered.

May 28th.—Again seen by Dr. McBride, who found the sequestrum more exposed, very little discharge, and not very offensive. He suggested the patient coming under Dr. Pritchard's care, as he was to stay in London.

June 6th.—The sequestrum was still fixed, there was very little discharge, no granulations, and less swelling. Again the decalcifying injection was ordered.

June 11th.—Sequestrum slightly movable by a probe, so removal was advised under a general anæsthetic, but this was objected to by his physician, Dr. Byrom Bramwell, on account of the condition of the patient's heart.

June 18th.—Finding the sequestrum now partially decalcified, portions of it were removed by means of forceps after the introduction of a ten-per-cent. solution of cocaine. The strength of the nitric acid injection was increased from 1 in 100 to 1 in 64.

June 22nd.—A large quantity of the softened sequestrum removed under cocaine and eucaine, by means of forceps, blunt hook and fine spoon. Acid injection to be continued.

June 26th.—More softened sequestrum removed in the same manner.

June 28th.—Last portions removed, leaving a deep cavity in the floor and posterior wall of the meatus lined with healthy-looking skin. The membrana tympani could now be thoroughly seen; it was looking healthy, and there was no perforation, no discharge.

July 9th.—Meatus normal. Sequestrum cavity contracting; no discharge.

Concluding remarks.—It was probable that the suppurative mischief was throughout confined to the wall of the bony meatus.

The acid injection practically decalcified the sequestrum in 20 days; in doing so the size was diminished and the substance rendered friable, so that it was easily broken up and removed.

There was no pain experienced in the removal, but this was chiefly due to the cocaine.

Fig. 4.

Tuberculosis of the incus.

Dr. WILLIAM MILLIGAN'S Case.

Tuberculous disease of the incus.

By W. Milligan.

The specimen was a section (with drawing) of an incus removed during the course of a radical mastoid operation from the ear of a child aged ten months who was suffering from tuberculous disease of the middle ear with involvement of the mastoid cells.

The history of the case was briefly as follows: For six months a purulent and fœtid discharge from the left middle ear had been present unaccompanied by pain or any symptoms of a sthenic nature. A few days before the child was seen slight puffiness over the left mastoid process was detected, accompanied by a slight elevation of temperature. When first examined the left meatus was found filled by a large mass of flabby bone granulation tissue. With the probe deep-seated softened bone was easily detected. The discharge was purulent, fœtid and streaked with blood. There was no facial paralysis. The glands under the ear were enlarged and tender. There was marked œdema over the mastoid process, and every indication of a chronic subperiosteal abscess. Operation was advised, but, owing to the indecision of the parents, was not performed until some days subsequently. At the time of operation a well-marked subperiosteal abscess was present. This was opened in the usual way and a fistulous track was found leading into the mastoid process, which was filled with soft carious *débris* and flabby granulation tissue. Careful curetting was done and the cavity of the middle ear opened by the removal of the bridge of bone between the middle ear and the antrum. The large mass of granulation tissue previously spoken of as filling the external meatus was now found to be growing from an area of softened bone upon the tympanic roof. This, together with the carious malleus and incus, was removed and the whole cavity thoroughly swabbed with pure carbolic acid.

FIFTH ORDINARY MEETING.

Monday, March 4, 1901.

THE PRESIDENT, SIR WILLIAM DALBY, IN THE CHAIR.

The following gentlemen were elected members of the Society:

CHARLES HEATH.
ROBERT FULLERTON.
FREDERICK WESTMACOTT.

The PRESIDENT announced that the Council had decided to hold the next meeting on May 11 at Edinburgh, in response to a warm invitation. It would be remembered that at the formation of the Society it was suggested that one day might be spent away from London. In order that the number of London meetings should not be reduced, an additional meeting would be held here on June 10.

A case in which the complete post-aural operation has been performed.

By ARTHUR H. CHEATLE.

A girl, *æt.* 18 years, suffered in infancy from suppuration in both ears. After some time the right healed, but the left continued to discharge with attacks of pain ever since. On the right side the posterior and inferior segments were replaced by a thin cicatrix, and it could be seen that the tip of the articular process of the incus had been lost and that an adhesion passed from the remains to the head of the stapes, from which another adhesion passed forwards. On

the left side a perforation was present in the posterior-superior segment, and a granulation could be seen coming from posteriorly. Adenoids were found and removed. The ear improved up to a certain point by ordinary methods, including purification and packing, but as a cure was not effected the remains of the membrane, the malleus and incus were removed, the last having lost a portion of its articular process. Ordinary treatment was then resumed, but as the discharge still continued to come from the attic, the complete post-aural operation was performed on November 20th, 1900, the antrum being found full of pus. Healing was complete towards the end of January.

The questions Mr. CHEATLE wished to raise on the case had reference to those of cholesteatoma shown by Dr. GRANT at the last meeting, cases in which the cholesteatomatous membrane had been left.

He asked:

Did the epithelial lining in his case differ from that lining a cholesteatomatous cavity?

If it did,

In what way did it differ?

Was a cholesteatomatous epithelial lining diseased *per se?* or was there some other permanent or temporary influence present which rendered *any* epithelial lining liable to desquamate?

The question raised by Dr. GRANT, following Siebenmann and others, as to whether a cholesteatomatous lining membrane could be safely left if the complete operation be performed, depended on the answers to these questions; for if the cholesteatomatous lining membrane was not diseased *per se*, but was caused to desquamate by the irritation of pus coming from a localised unhealed and therefore uncovered surface (as suggested by Mr. BALLANCE), or from any other temporary cause or causes, then we might, after treating such local cause or causes, and laying the cavities into one with a large aperture, safely leave the lining membrane. On the other hand, if the cholesteatomatous membrane be diseased *per se*, then it would be unsafe to leave it, and it must be thoroughly

removed. He wished to point out that the manner in which the epithelial lining is formed, both in cholesteatoma and after the complete operation without grafting was very similar, namely, by extension from surrounding parts; but it must be remembered that in the former case it started under pathological, and in the latter under healthy conditions. He thought it might be said with truth that the recurrence of cholesteatoma was more in evidence where the Schwartze operation was performed; when the cavities were not thoroughly exposed and dealt with. Dr. PRITCHARD and Dr. TILLEY, in the last session, showed cases in which the cholesteatoma had taken the law into its own hands and performed the complete operation so thoroughly that it would have been difficult for an uninitiated observer to say whether nature or the surgeon had operated. It would be interesting to hear from time to time how these cases go on.

The PRESIDENT said he had examined the case, and the result seemed to be quite perfect. The surface was glistening and dry, and he thought nothing could be better.

Dr. URBAN PRITCHARD said that case practically opened up the whole question of the pathology of cholesteatoma, upon which they all had their own pet views. His own was as follows: that it was exactly like those cases in which there were accumulations of pure epithelium in the meatus, which might go on enlarging it and do a great deal of damage. He believed in all cases it was due to some irritation, in consequence of the continuance of which, for a long time, there was a bad habit of desquamation. First there was localised dermatitis, and even when the irritation of that was past the bad habit of desquamation continued. He would not say whether that could be called disease or not, but he was certain that in many cases that bad habit was overcome. He felt certain that in cholesteatoma in the deeper cavities it was due to some suppurative poison getting in through the perforation, usually through the membrana flaccida to the attic and antrum, irritating that mucous

membrane so that it took on a desquamative condition, as if it were skin. As it was all locked up, the irritation persisted. When the cavities were opened up by operation, so that they could be cleansed easily, the irritation was removed, but they could not be quite certain that the bad habit had been removed. But it would more easily pass off than in the case of the meatus, where they had the skin to deal with. The logical conclusion was that efforts should be directed to getting the mucous membrane as healthy as possible, and therefore he had been in the habit of mopping the whole cavity out with pure carbolic acid, in order to destroy as much as possible of the septic material and leave a healthy lining membrane behind.

In reply to the PRESIDENT, he said Mr. CHEATLE'S was a complete post-aural case, it was not a case of cholesteatoma. Mr. CHEATLE had asked how that healed surface differed from the membrane lining an ordinary cholesteatomatous cavity. All he could reply was, that one seemed to him to be the epithelium derived from skin and the other from mucous membrane.

Dr. BRONNER said that since the last meeting he had looked up numerous cases of so-called cholesteatoma, which were not uncommon, and they had all done well, without treatment by transplantation of skin. When found in the middle ear, if scraped, they healed up. He thought it necessary to ensure the presence of air, and then there was not so much exfoliation as when the cavity was shut off. He thought the great point was to make an opening through the mastoid process or through the meatus, and secure free passage of air over the cavity. He regarded the question as very important, but thought we knew little about it. Many divided the cases into pseudo-cholesteatomata and true cholesteatomata. True cholesteatomata, as described by Virchow, were very rare, and required treatment by transplantation of skin.

Dr. DUNDAS GRANT said it was a pleasure to him to know that the case he brought forward at the previous meeting had been indirectly the means of bringing out so much valuable information, and he was sure that various members

had been thinking over the matter since. Those members appeared to have come round very much to the views which he then expressed. Professor PRITCHARD had now stated what was totally in agreement with what he himself urged, that there were certain cases in which the cholesteatomatous membrane could be left. In favourable cases the whole cavity could be opened up freely and then safely left. In some cases there was a considerable area of granulating surface which might take some time to heal, and probably during that healing infection might take place. These were not favourable, and therefore he did not urge that this method would be applicable to every case. They knew that sometimes the cholesteatomatous change extended into the cavities in the subjacent bone, which produced a further source of irritation. Another condition required would be a fairly homogeneous, smooth and not too thick condition of the lining, which, after opening and thoroughly cleansing, could be left. He was not aware that any investigations had been made as to the depth at which cocci were to be found in a cholesteatomatous lining, and it would be interesting if sections were made from a cholesteatoma and carefully stained, so that it might be seen whether cholesteatoma was a disease *per se*. He believed the danger lay in the physical circumstances, namely, the narrow-necked bottle-like shape of the cavity, which it should be their endeavour to convert into an open basin-like cavity. By that means the danger was so minimised that it was worth while to try his plan to see whether the result would not be as good as in the woman they had seen.

Mr. SECKER WALKER said in doing the complete mastoid operation there would be much cutting or burring of bone, and as it was as easy to graft a large surface as a small one, it would be wiser not to leave any suspicious membrane, which he had always believed swarmed with organisms. Dr. GRANT had said that small projections sometimes passed deep into the bone. For that reason, he (Mr. WALKER) would take the whole cholesteatoma out, especially as carbolic acid would not go thoroughly into those small cavities. Three weeks

ago he did a complete mastoid operation, where the whole of the mastoid process was hollowed out and contained cholesteatomatous masses. In this case he removed all the so-called membrane, and did not follow Mr. BALLANCE'S method of leaving the deeper parts of the mastoid cavity to granulate over, but covered the whole part with two pieces of epithelium followed by gold-leaf cut into strips one-third of an inch wide and one inch long. The case was dressed on the third day and the gauze dressing taken out on the fifth, Four days ago the part was dressed and had done very well, the dressing being comparatively dry.

Mr. BALLANCE said the question of the so-called membrane in cholesteatoma and that of the real origin of cholesteatoma had been raised. With regard to the origin of the ordinary forms of cholesteatoma, he thought there was always ulceration, and every modern book on pathology told them so. Ulceration was a necessity to the formation of cholesteatoma. In ulceration of the temporal bone, even though the ulceration was small, the rest of the cavity might be irritated and the epithelial lining would desquamate squamous and polygonal cells, which were seen under the microscope to form the bulk of the cholesteatoma.

With regard to the so-called membrane of cholesteatoma, two kinds were mentioned. The first was a thin fibrous one, and was occasionally present in cholesteatoma in the temporal bone, the interior of the membrane being filled with ordinary cholesteatomatous material, such as epithelial cells, cholesterine, and so forth. That form was also found in the body elsewhere under the name of "pearl tumour." It was described by Schwartze* in his admirable book on the pathological anatomy of the ear.

With regard to the ordinary form of cholesteatoma, which was always being met with in operations, he asserted there was no membrane, and none was mentioned in any pathological work. The so-called membrane was a portion of the

* In the great majority of cases of so-called Cholesteatoma in the temporal bone we are dealing with nothing more than a retention of inflammatory products the result of suppurative processes (Von Troeltsch).

cholesteatoma, and was simply owing to some of the cells having by pressure been forced together and formed a flattened apparent membrane.

He wished to ask whether Dr. GRANT proposed to leave a part of the cholesteatoma behind in his operation. If that so-called membrane were removed they would see underneath an irritated epithelial surface in some parts and ulceration in other parts; and he could not imagine, either from the point of view of modern pathology or from what they knew of cholesteatoma and its ordinary treatment, why a portion should be left behind. It was only by a real knowledge of the nature of cholesteatoma that a true practice of surgery could be founded. He maintained that leaving any part of the cholesteatoma behind was not the right practice. He (Mr. BALLANCE) thought it was supremely important that they should clear their minds of the idea of a living membrane being part of an ordinary dead cholesteatomatous mass.

Dr. PRITCHARD asked whether Dr. GRANT meant the membrane which Mr. BALLANCE spoke of, or the layer of epithelium on the bone itself. He (Dr. PRITCHARD) referred to the lining of epithelium on the bone itself.

Dr. GRANT said that was what he meant. "Matrix" was the best term to apply to it. He asked members to suppose that the walls of the cavity in the bone were ulcerated and granulating, just like an ulcer upon the surface of the body, but hollow instead of flat. When the ulcer healed it did so by the proliferation of epithelium over the surface. The cholesteatoma was thus the result of a healing process, which extended by the epithelium gradually proliferating over the surface of the interior of the cavity. He considered that the last stage was reached when the part farthest from the orifice was at length covered with epithelium. Under the influence of moisture, or of microbilic invasion, the cells there began to desquamate, and then "cholesteatomatous" matter formed. He did not mean every little cheesy collection found on opening the middle ear, but layer after layer of epithelium given off from the matrix. His efforts were directed to scraping out all those

desquamating cells and leaving the deepest layer, which was on the previous ulcerating surface (like the cicatrix of a healed ulcer).

A case of closed meatus following a Mauser bullet wound.

By C. H. Fagge.

T. R., *æt.* 22, was hit by a Mauser bullet at Middleberg on May 29, 1900.

Mr. A. D. Fripp, to whom Mr. Fagge was indebted for permission to bring the case before the Society, writes in the *Lancet* of September 22, 1900, p. 895:

"The bullet passed inwards and slightly downwards and backwards through the zygoma on the right side. There was complete facial and auditory paralysis and considerable involvement of the fifth cranial nerve on that side. No exit wound could be found. There was such violent bleeding from the external auditory meatus that, after repeated trials of other means of arresting it, I was driven to tie the common carotid. As there was also commencing optic neuritis with rigors and some swelling just below the mastoid process, I thought it wiser to put a ligature round the internal jugular at the same time. The hæmorrhage ceased, the wound in the neck healed perfectly, and for a time all went well, but later on an abscess developed in the pterygoid mastoid and parotid regions, and hæmorrhage from the meatus recommenced.

"So I made an incision widely curved from the entrance wound of the bullet backwards above the pinna and downwards behind it to the tip of the mastoid, and turned the flap downwards with the pinna attached.

"The condyle of the mandible and several fragments of bone derived from the ramus and from the pterygoid plates were found lying loose in a large abscess among the pterygoid muscles and were removed.

"The abscess cavity was drained and the hæmorrhage

arrested by plugging and by leaving a pair of Spencer Wells forceps on a vessel in the periosteum of the mandible.

"The patient made an uninterrupted recovery and, despite the loss of one of the condyles of the mandible, he can now masticate ordinary diet, including chicken and beef. The optic neuritis did not progress; on the contrary, Mr. CARGILL thinks that it may be clearing up.

"In fact, the subject of these extensive injuries has now no signs remaining except the facial paralysis, the unilateral deafness and the scars."

The skiagram confirmed the above injuries and showed no bullet. The patient was referred to Mr. FAGGE for treatment last November; all the external scars were firmly healed; the meatus was wide, about three-quarter inch deep, ending abruptly in an area of granulation tissue from which was removed a spicule of bone; the probe would not penetrate farther.

Watch $\frac{\text{R. o}}{\text{L. n}}$ T. F. Rt. Md. > Ms. Md. +
L. Ms. > Md. Md. n.

Weber's test referred to Rt.

When he attempted to valsalva nothing was heard with the otoscope in the right ear. The right facial paralysis was complete. Taste on the right side of the tongue had never been affected, and is now quite normal to salt and sweet substances. The optic discs are normal.

He asked whether operative treatment was advisable.

The PRESIDENT said it appeared that the wound had not extended to the tympanic cavity. He remembered a case in which a man loaded a pistol in six chambers, put the pistol to his ear, and pulled the trigger. The bullet went clean through the tympanic cavity and through the aqueduct of Fallopius, as a result of which facial palsy was instantaneous. Eventually healing took place, leaving facial palsy and total deafness of right side, but no one knew where the bullet went.

Mr. CHEATLE said Mr. FAGGE asked whether it would be worth while to open the meatus? They knew the middle

ear was not seriously injured, as taste was present, showing that the facial nerve was injured outside the bony canal, therefore he thought it would be well worth while to try to open it.

Dr. DUNDAS GRANT said the tuning-fork at the vertex was heard loudest in the affected ear, which would indicate that the auditory nerve was still useful.

Mr. LAW doubted whether the middle ear or labyrinth was intact, and he understood Mr. FAGGE to ask not only whether by operative procedure hearing would be restored, but whether the patient was not running an unnecessary risk in having a closed meatus. He (Mr. LAW) thought the tympanic cavity was damaged, either by the bullet, by hæmorrhage, or by abscesses in the neighbourhood. He would not expect the patient to derive any great benefit in hearing from an operation, which would be somewhat difficult in any case to carry out.

Dr. MILLIGAN thought it would be justifiable to operate, in order to remove the cicatricial web. He suggested, as a method of keeping it open, the chipping away of some of the bone of the posterior wall, which would have considerable influence in preventing retraction.

Mr. FAGGE asked by what signs Dr. LAW judged that the middle ear was impaired. The opinion that the middle ear was intact, founded on Weber's test and evidence that the chorda tympani was intact, was his (Mr. FAGGE'S) reason for bringing the case before the Society.

Mr. LAW said if it had not been impaired he would have expected to find the patient hearing better by both air and bone conduction than at present; but he would not like to speak strongly on this point from such a cursory examination of the patient's hearing capacity.

Mr. DE SANTI said that he thought the patient would be well advised to have no operation done. He did not appear to suffer much in hearing on that side, and he thought an attempt to destroy the cicatricial band would end in failure.

Dr. LAMBERT LACK said he had a case in which a man poured sulphuric acid into his ear to relieve earache, with

the result that he got complete cicatricial stenosis of the meatus. There was no difficulty in remedying such a condition, and having excised the scar-tissue he turned in a flap of skin, which partially lined the new meatus, and let the rest of the wound granulate. In the present case, unless dangerous symptoms arose, he would leave the patient alone.

Dr. MACNAUGHTON-JONES thought no danger was to be anticipated in attacking the cicatricial band. Whether there was any remains of hearing or not, it was justifiable to get that scar out. With reference to a case he showed himself some months ago, in which there was complete blocking by cicatricial tissue, the hearing was remarkably good. The patient was wearing her tube and all discharge had ceased.

Dr. PRITCHARD said he would be inclined to leave the case alone. If, however, the patient asked whether there was any possibility of benefit resulting from operation, he would put the matter before him and let him decide.

Mr. BALLANCE asked whether the facial nerve was divided. If so, he presumed suturing would be done. He saw no harm, as far as hearing was concerned, in removing the scar. He thought the nerve was divided outside the sterno-mastoid foramen, so that it was an ordinary surgical case. If the two ends of the nerve could not be brought together, an animal's nerve should be put between. That was the main element in the case; the other was quite secondary, and could easily be dealt with.

Mr. DE SANTI suggested that there might be extreme difficulty in finding the facial nerve, in view of the amount of scar-tissue in the neighbourhood.

Mr. BALLANCE thought there would be no difficulty in finding the main trunk, and the course of the nerve being known, the other end could be found, whether there was ear-tissue or not.

Case of acute meningitis following suppurative otitis media. Operation. Recovery.

By Lambert Lack.

The patient, a girl aged 17, came under Mr. Lack's care on November 9th, 1896. She had suffered from purulent discharge from the ears for many years, and was very deaf. Ten days previously adenoids had been removed and all went well until seven days after the operation, when there was a sudden onset of earache, frontal headache, and rise of temperature. Counter-irritation to the ear, a purge, etc., were ordered. The next evening he first saw her. There was then much discharge from the ear, the pain in the ear, restlessness, headache, etc., continued, there had been sickness, and the temperature was 102° F. There was no mastoid tenderness or swelling. The following morning the patient was very ill indeed, had been restless and delirious all night. Constantly sick, passing everything under her, could not be roused, but was evidently in pain. There was still no local swelling.

The diagnosis of acute meningitis was made and operation was performed at once, exactly forty hours after the onset of the first symptom.

The antrum and tympanum were opened up in the usual way, but no pus was found. The middle fossa was next freely opened by removing the entire roof of the antrum and attic. The bone was extremely thin, and on removing it a few drops of turbid fluid escaped. The dura mater over an area as large as a shilling was discoloured and softened, resembling damp dirty white blotting-paper. A crucial incision was made right through this sloughy patch, and a considerable amount of turbid serous fluid escaped. The brain membranes and cortex appeared intensely congested. The temporo-sphenoidal lobe was freely explored with sinus forceps, but without result. The lateral sinus was also exposed, but was found to be healthy.

After history.—All that day, and the following night and day, the patient remained unconscious, very restless, and

delirious at times. The temperature ranged from 102° to 103° F. There was constant sickness, nothing could be given by mouth, and nutrient enemata were not retained. Thirty-six hours after the operation teaspoonfuls of hot water with a little Valentine's extract were given, and, being retained, were repeated every half-hour.

The next day the patient was distinctly better, though still restless and in pain. A hypodermic injection of morphia (gr. $\frac{1}{4}$) gave five hours sleep. The sickness had ceased and Valentine's extract was continued in teaspoonful doses, and nutrient suppositories were also given and were retained The fourth day the temperature touched normal and slow recovery ensued. Facial paralysis was noted as the unconsciousness passed off. For many days the patient was somewhat aphasic, having apparently forgotten certain words, although answering questions rationally. She slowly gained strength, but was unable to leave the hospital until ten weeks after the operation.

The discharge from the wound, examined by Dr. HEWLETT, contained strepto-cocci and a small bacillus.

The chief points of interest were, perhaps, the rapid increase of the symptoms and the grave condition of the patient forty hours after the onset; the almost hopelesss nature of the case and the favourable result. The cause of the facial paralysis, which was quite complete for two years, then first commenced to improve, and is now not very marked. Was it due to the meningitis or to injury at the operation? The long duration of it and ultimate recovery are also remarkable.

Mr. CHEATLE asked what was wrong with the ear before Dr. LACK operated. Dr. LACK said it was attic disease, but he had not said what was the condition of the ear before operation. He suggested that a local meningitis was present, infection having taken place through the petro-squamosal sinus.

Dr. LACK said he called the case one of acute meningitis following suppurative otitis media. There was no perforation through the roof of the attic to the middle fossa.

Mr. Hugh E. Jones said he had reported a case in which there was paralysis of both external recti and the opposite facial nerve, and double optic neuritis which had resulted in partial atrophy of the optic discs. He found a small extra-dural abscess, but did not incise the dura in his operation. Recovery was slow, but was eventually complete, with the exception of contraction of the fields of vision and lessening of the acuity of central vision.

Teaching diagrams for the explanation of Weber's and Rinne's tests.

By Dundas Grant.

Many members of the Society being engaged in teaching the elements of otology, the following diagrams were offered for their consideration as a means of facilitating the explanation to students of the classical tuning-fork tests.

In the following diagrams the number of lines passing

Fig. 5.

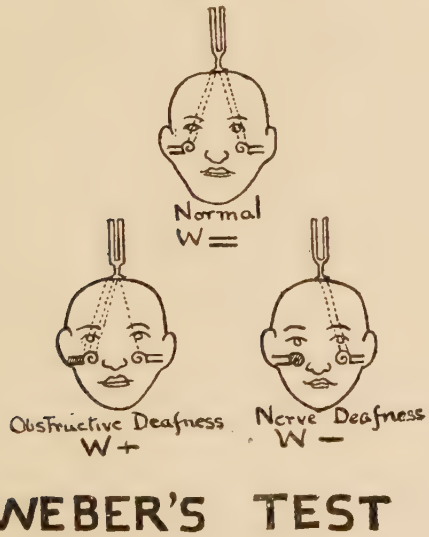

from the tuning-fork through the bones to the internal ear,

or through the air to the middle ear, are intended to indicate the degree of audibility of the sound. The black shading indicates the site of the lesion as in the conducting apparatus or the internal ear.

In the above diagrams it will be seen that normally the tuning-fork on the vertex is heard equally in both ears, or, as it seems, in the middle of the head. In the case of a unilateral lesion in the conducting apparatus the fork on the

FIG. 6.

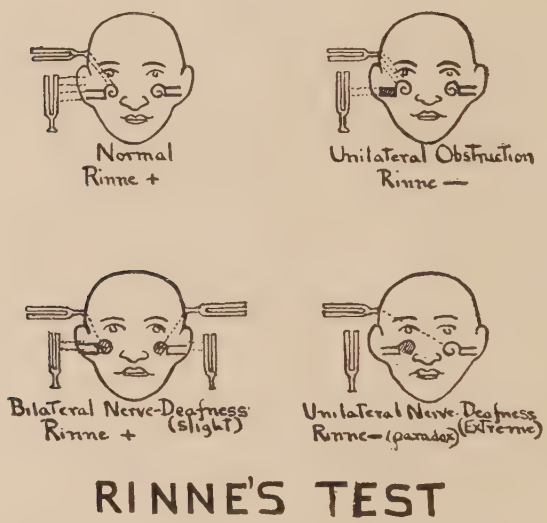

vertex is seen to be heard louder in the affected ear, the opposite holding good in the case of unilateral nerve deafness.

It will be seen that in the normal ear the tuning-fork is heard better through the air than through the bone, and Rinne's test is said to be positive. In obstructive deafness it is shown that the tuning-fork is heard better through the bone than through the air, and Rinne's test is negative. In bilateral nerve deafness, the ratio of air conduction to bone conduction is maintained, and the fork is heard better through the air than through the bone, Rinne's test being, therefore, positive. In unilateral nerve deafness of the highest degree,

it may be found that the tuning-fork is heard better through the bone than through the air, and Rinne's test is, therefore, negative; but this is owing to the fact that the air conduction of the affected ear is (as the diagram shows) compared with the bone conduction of the opposite ear; this may be called a paradoxical negative Rinne, and forms an exception to the general rule that a negative Rinne indicates obstructive deafness; it may be checked, however, by means of Weber's and other tests.

Three Specimens.

(i) *Absence of tendon of the tensor tympani.*
(ii) *Pigmented warty growth from the auricle of a woman, aged 50 years.*
(iii) *Caries necrotica of the outer antral wall from a child, aged 4 years.*

By Richard Lake.

(i) This specimen was obtained in the course of a series of dissections of the temporal bone, and no history could be obtained. Mr. Lake could not help feeling that the tendon was cut some considerable time before death, the absence of scar being not very important. Had it been congenital, he believed the chorda tympani would have followed a similar course to that he described in the *Lancet* some years back.

(ii) Pigmented horny wart of auricle—left—removed from a female, aged 50. The patient was a woman, aged, of stout but strong build, who gave a history of a blow on the left ear some months before. There were no signs of glandular involvement. The growth was removed, and is shown to-night; the wound healed by primary union. The microscope showed the growth to be dipping down into the subcutaneous tissues and to be surrounded by small cells.

(iii) A temporal bone—right—of a four-year-old child, who died from meningitis. The outer wall of the antrum was necrosed, eroded and perforated. There were signs of inflammatory action in the inner surface of the squamous portion

on a level with the upper part of the sequestrum. The ossicles are in the small vial.

A foreign body which had remained innocuously in the meatus for 26 years.

By St. Clair Thomson.

Dr. Thomson said the small pebble was in the patient's ear from the age of four to his thirtieth year, and had caused no inconvenience. He had been able to move it about in his head, and he came for advice simply because it was surrounded by wax and he could no longer move it. It was found to be wedged in between the attic and the external auditory meatus, not lying on the floor of the latter.

Dr. Macnaughton-Jones said he had recorded one case in which a grain of shot remained in the ear from the age of five to the twenty-second year. When five years of age the child put some shot in her ear, and one grain was removed soon afterwards. At the age of twenty-two she came complaining of deafness, and he removed a large plug of wax; still there was a black body at the bottom of the meatus; syringing brought it away. Hearing was perfectly restored, and there was no trouble afterwards.

Mr. Cheatle said he had lately removed an earwig from an ear, the third case of the kind on record. He insisted that in removing foreign bodies from the ear, especially if instruments were to be used, strict antiseptic precautions should be taken.

Mr. Milligan thought the most important moral of the case was that a foreign body might lie in the ear for a long time without damage, and it was important to impress that upon patients. The damage in such cases was due to the vigorous attempts at removal, whereas, if the case were allowed to wait until proper advice could be obtained, many a middle ear would be saved.

Dr. Pritchard said he had the case of a man in whose ear

a cherry-stone remained for fifty years. The man remembered it perfectly well because of the vigorous attempts at removal, such as Dr. MILLIGAN had mentioned, and his parents would on that account have nothing further done. The foreign body came away on simple syringing.

Mr. LAWRENCE said a short time ago a woman, aged fifty-two, came complaining of deafness, and it appeared she had had a bead about a quarter of an inch broad in her ear since the age of six. Though it had sharp edges it had remained there forty-six years.

Suppurative otitis media, temporo-sphenoidal abscess. Operation. Hernia cerebri, maniacal excitement. Recovery.

By HUGH E. JONES.

Alfred T., *æt.* 16, admitted to Liverpool Eye and Ear Infirmary, October 17th, 1900.

Family history.—Two brothers have occasional earache. One is very deaf and the other slightly so. No history of tubercle.

Personal history.—No scarlatina nor influenza; measles when 2½ years old. The patient's mother says he had discharge from ears off and on since the attack of measles. The patient himself dates the discharge from three years ago, and attributes it to his being boxed on ears at school. The discharge more than two years ago was offensive, occasionally bloodstained and copious. The mother cannot recall any early symptoms pointing to brain complication except that occasionally during the few months preceding the acute illness the boy would "shake his head and say he had a pain in it." *Three months before admission* into hospital (two months before serious illness) was said to be stupid at his work, and when asked what was the matter with him used to reply that he felt "dazed," and the right ear began to be painful. *One month before admission* a slight swelling appeared over right mastoid, and severe pain, referred to the vertex, came on (and continued until the brain abscess was

evacuated). At this time and during the *next fortnight* the boy was giddy—had put his hand on walls, etc., while walking to steady himself, and "things went round"—he also "saw one object as two or three." During this period he did not work, but went to a doctor's surgery twice a week. During the *last fortnight* before admission the boy remained in bed. He now suffered intense headache, rarely slept at night, but dozed during the day, dreaming all sorts of extraordinary things (he could hardly be convinced when awake that his dreams were not real, but he had no actual delusions); took hardly any food and wasted rapidly.

A few days before admission the boy vomited several times and had slight shivers. He was quite intelligent throughout but dull and quiet (he is naturally a bright noisy boy). During the time he was in bed at home he was not seen by the doctor, but was seen daily by the district nurse, who applied hot fomentations and syringed the ear with lukewarm water. There is no record of pulse and temperature for this period. Nearly the whole of the above history was obtained after the operation. The patient travelled to the hospital by 'bus and electric car, and had also to walk 200 or 300 yards. He then waited in the out-patient room as an ordinary patient.

Condition on admission. General.—Pale, grey, emaciated face, apathetic with a shade of anxiety; the boy answered all questions quite intelligently, promptly and fully (answers not delayed nor monosyllabic). P. 44, dicrotic but regular. T. 97° Fah. R. 14. Special nerves: pupils equal, not dilated, acted to light. No squint. Slight optic neuritis, more marked in right eye than left.

Slight left facial paresis (opposite lesion). Left-hand grip stronger than right (right-handed boy, the patient exclaiming that right hand felt weak). No loss of sensation observed (examination very cursory).

Hearing.—Right watch on contact. Left watch at 6 inches. Both membrana tympani perforated. Offensive discharge from both middle ears.

Mastoid.—Swelling and tenderness without fluctuation, practically confined to mastoid area.

Operation.—(October 17th, day of admission into hospital.) Schwartze mastoid operation and trephining over temporo-sphenoidal lobe.

The whole of the interior of the mastoid was found to be broken up and full of pus, bone *débris*, and granulations. The posterior wall and tegmen were unbroken, but rough and bare. There was no special indication in the condition of the mastoid as to the direction in which the infection had spread. In order to save time, the antro-meatal partition was not removed and the tympanum was not dealt with. The cavity having been cleansed and packed, a disc of bone was removed from the squama immediately over the roof of the antrum. No extra-dural abscess was found. Strong pulsations were apparent through the undivided dura, and it was decided to postpone exploration of brain. No change in symptoms.

October 19th, 9 A.M. Operation of October 17th continued. The dura, still pulsating strongly, was incised. Grooved director passed into the brain in the usual directions drew no pus, but was felt to glide over a smooth curved tense surface in the posterior part of the temporo-sphenoidal lobe about half an inch from the surface. The trephine opening having been enlarged upwards and backwards, this elastic body was now incised with a scalpel and proved to be a large abscess, with a distinct though thin wall.

The first incision in the dura was nearly horizontal; a vertical one, three-quarter inch long, was now made across the other near its hinder end. On enlarging the opening into the abscess with dressing forceps the cavity was rapidly evacuated, ragged brain edges being carried through the dural incision, and soon the purplish-coloured inner wall of the abscess bulged into the wound, completely closing it. He did not consider it advisable to wash out the cavity, but explored it carefully with the forefinger, which passed readily upwards and backwards up to the second joint. He was not able to discover any branching recess, and wherever he felt it the wall was smooth. Portions of cortex protruding through the dura were carefully removed, the wound was cleansed and stitched

up the scalp wound to the level of the lower border of the trephine opening.

The fluid from the abscess resembled curds and whey, the more liquid portion being watery, so that one wondered whether, in the sudden lowering of tension, a collection of fluid in one of the larger fissures or in the lateral ventricle had not discharged into the abscess cavity. This idea influenced him in deciding not to wash out the cavity. The abscess seemed to be about the size of a hen's egg and situated in the upper part of the posterior half of the temporo-sphenoidal lobe. It was apparently surrounded by healthy brain tissue.

Course of case after operation.—The pulse-rate remained low, 50 to 60, with three rises to 80 for four days, and then steadily improved for a week, after which it kept fairly constant at 80 to 90. The temperature on evening after operation was 99·80°, and afterwards kept below 99°. Respirations followed pulse-rate closely. The bowels did not act until the eighth day after admission, in spite of calomel; after that date enemata were employed every third or fourth day.

For the first five days a large quantity of cerebro-spinal fluid was lost. Fresh outer dressings had to be applied frequently.

For a month after operation, hearing power on *both sides* was very poor. For a week or ten days the boy was excited, noisy and talkative, and had to be closely watched. The moment the nurse's back was turned the boy would spring out of bed and make a raid on the kitchen, drink the milk, gobble up the nurse's supper, and carry off any other articles of food he could find to secrete them in his bed.

His language—though all his friends declared him to be usually in every respect a well-behaved boy—was often painfully bad. Whenever remonstrated with, he would promise hysterically to be a good boy, and the next moment commit the same offence. His appetite was voracious and his loud demands for food incessant, though he had been put on full diet three or four days after operation. He was clearly not responsible for his actions. The excitement

Photograph of patient after operation for temporo-sphenoidal abscess.

Mr. Hugh Jones's Case.

gradually subsided, and within a month of the operation the boy became the brightest and most docile patient in the ward.

The patient retained only the most confused memories of the fortnight preceding and the fortnight succeeding the operation.

Healing of the wound.—The first complete dressing was made on the fifth day; suppuration was going on under the skin flaps. All the stitches were removed and the wound henceforth treated as an open one. The moderate-sized hernia which formed was treated by swabbing with pure carbolic acid and firm padding. The patient left the hospital on December 22nd (sixty-sixth day after operation), and went back to work (without the permission of his parents or myself) the first week in February 1901, wearing a pad over the cicatrix.

The present condition of the patient (March 1st, 1901) was as follows:

Right ear: Perforation in lower posterior quadrant of membrana tympani; ossicles are in good position; no granulations can be seen; slight moisture in tympanum. Watch heard at 5″. Left ear: Perforation as in right, but tympanum quite dry. Watch at 10″. Bone condition full time.

Cicatrix firm but contracting very slowly. There is still considerable separation of the edges of skin, allowing a slight bulging of the cranial contents, the pulsation of which can be both felt and seen.

The margins of true skin were freely movable over the underlying bone, and could be easily brought together if it was thought worth while to disturb the vascular cicatrix.

Remarks.—Whereas some uncommon symptoms were present in this case, some of the classical ones were absent.

When the high degree of intracranial tension, as indicated by the low pulse and respiration ratio, was taken into account, the absence of the three following well-known symptoms seemed to be worthy of note:

(*a*) Dilatation of or inequality of the pupils.

(*b*) Slowness of cerebration. The patient was certainly dull and talked little, if at all, unless spoken to, but there was no delay in answering questions nor any particular brevity about the answers. It must be admitted, however, that the maniacal excitement following the operation was in very marked contrast to the patient's demeanour before the event.

(*c*) Non-pulsation of the brain at the trephine opening.

Mr. JONES suggested that this sign is dependent to a large extent upon the position of the abscess relative to the trephine opening. In his case the anterior extremity barely reached as far forward as the posterior margin of the original opening.

The following symptoms (some of them rare) were present, and were of special interest:

(*a*) Weakness of hand-grip on same side as the brain lesion. This symptom for a moment directed the attention to the cerebellum, but the absence of other confirmatory signs, such as staggering gait and yawning, led him to seek for another explanation of the symptom — commissural fibres (?).

(*b*) Paresis of the opposite side of the face without any corresponding affection of the arm and leg. This was remarkable, considering that the abscess was far back and apparently clear of the cortical motor centres, and that there was no evidence of pressure on the oculo-motor nerves, which is often present in association with cortical facial paresis, due to pressure from temporo-sphenoidal abscess.

(*c*) Deafness of the opposite ear. The position of the abscess in the middle and superior temporal convolutions presumably accounted for this. It was much greater than could be accounted for by the local disease of the left ear.

(*d*) Complete anorexia before and extreme voraciousness of appetite after operation. Whether this was to be taken as merely a general result of destruction of brain tissue, or as an indication that some special area connected with the gastronomic functions was destroyed or pressed upon, he was not prepared to say.

In conclusion, he wished to take this opportunity of express-

ing his conviction that the early detection of brain abscesses and, if possible, of *latent* abscesses, is of the highest importance to operating aural surgeons. What guarantee has any surgeon who is about to perform a radical operation for chronic suppurative otitis that there is not present in close proximity to the field of his operation a latent brain abscess? Are there no signs by which such an abscess could be detected?

He suggested that it is our duty to register carefully all the symptoms, however trifling they may appear to be, in cases of chronic suppurative otitis, which may by any possibility indicate a brain lesion. He referred especially to subjective and psychical signs.

For this reason he had entered into many wearisome details in recording the early history of this case, and regretted that his personal acquaintance with it only began when symptoms of extreme urgency had arisen.

Suppurative otitis media: caries of petro-mastoid; facial paralysis. Curetting operation. Death from convulsions twenty-eight hours later.

By Hugh E. Jones.

(Temporal bone, meninges, and microscopic sections shown.)

E. L., a boy, *æt.* 1 year 7 months, was sent to the Liverpool Eye and Ear Infirmary by Dr. Dowling, of Haydock, on August 15th, 1900. The child had acute suppurative otitis (L.) when four months old. This resulted in chronic suppuration with caries (four pieces of bone came away) and, four months before above date, in complete facial paralysis.

On admission to out-patient department there was purulent discharge from meatus and from a mastoid fistula, the cavity of the ear was filled with granulations, and no trace of membrana tympani or ossicles could be found; the cervical glands were moderately enlarged but were not softening.

Having a strong dislike to operating on the temporal bones of young children, I ordered the ear to be gently

syringed twice daily through a Lane's tube with glycerine of carbolic lotion, and alcohol and iodoform drops to be instilled, thereby hoping to postpone operation and at the same time prepare the part should any urgent necessity for operation arise.

Two months later (October 17th), as no progress was apparent, it was decided to operate at an early date, but owing to some misunderstanding the child was not again seen until he was admitted into the infirmary on January 8th, 1901. No new symptoms had been observed by the mother during the interval, and nothing was observed on admission which indicated intracranial extension. T. 97° F.

For three days before operation the ear and sinus were carefully irrigated twice a day with Lot. glycer. ac. carbolici and lightly packed with iodoform gauze.

January 11th, 5 P.M. *Operation.*—Incision over mastoid passing through the fistulous opening; auricle reflected forward. A large cavity in the petro-mastoid bone was thus exposed without the removal of any bone. After removal of granulations from the cavity it was evident that the whole of the osseous tegmen, the posterior and superior walls of the meatus, and the anterior part of the labyrinth were missing. The sigmoid sinus and dura mater of the posterior fossa were not exposed.

Free hæmorrhage occurred while the anterior and inner end of the cavity was being curetted. The wound was well washed out with carbolic lotion and packed with iodoform gauze. The operation and anæsthetic were apparently well borne. The child was sick once that evening, but slept well all night. Next morning (January 12th) the patient was unnaturally quiet, but did not otherwise appear to be ill. At 10 A.M. he vomited after taking some milk; slept heavily from 1 to 3 P.M.; convulsions commenced at 3.20 P.M. and lasted, with slight intermissions, until 10 P.M., when the child died. The temperature had risen steadily between 3 P.M. and 8 P.M., when it was 103°. He saw the child at 5 P.M. during an intermission in the convulsions.

The lips were somewhat cyanosed, pupils semi-dilated,

respirations twelve per minute, regular but with long intervals (not Cheyne-Stokes). Dr. Lithgow, the house-surgeon, made a careful examination of the chest, but could not detect any signs of pneumonia.

Post-mortem examination.—Permission was obtained to examine the head only.

There was no marked increase of cerebro-spinal fluid. The pia-arachnoid over the convexity of the frontal lobe was opalescent and much thickened; there was no fluid pus nor yellowness of the exudation; no flaky lymph on the surface —in fact the exudation appeared to be interstitial and gelatinous. The thickened portions of membrane were studded with minute points of hæmorrhage. The pia peeled easily from the brain, which was firm and apparently healthy throughout. No tubercles were found. The changes did not extend to the under surface of the brain. The dura over the base of the skull was smooth and not discoloured. The ventricles of the cerebrum were not distended, and the lining membrane appeared healthy. The dura forming the roof of the large cavity in the temporal bone contained a large vein running obliquely backwards to join the superior petrosal sinus near its junction with the lateral sinus. The sigmoid sinus contained a clot which seemed to be crumbling but not septic. The temporal bone, portions of the thickened meninges and the cerebellum, pons and medulla were preserved in ten-per-cent. formalin solution. Horizontal section of the temporal bone at the upper level of the internal auditory meatus showed the greater part of the labyrinth to be missing, the abscess cavity reaching to the inner wall of the vestibule. The walls and contents of the internal auditory meatus looked healthy. The posterior wall of the mastoid and the floor of the tympanum were not destroyed.

The following pieces of tissue were submitted to Dr. Warrington, of the Thompson Yates Laboratory:

1. A portion of the dura covering the tympanum, including a part of the above-mentioned vein.
2. The auditory nerve.
3. A thin section of bone.

4. Clot from the sigmoid sinus.

5. Portions of the thickened pia-arachnoid from the convexity of frontal lobe.

Dr. WARRINGTON kindly reported as follows :

No. 5 contained diplo-cocci (pneumoniæ) but no bacilli.

Nos. 1, 2 and 4 contained no micro-organisms.

No. 3 was not examined.

Remarks.—Was the meningitis due to interference with the granulations in the petrous bone and growing from the dura; or, had the membranes been in the thickened condition in which they were found for some time before the operation ?

The absence of micro-organisms from the dura lining the abscess cavity, and from all the tissues examined except the pia-arachnoid, seems to me to indicate that the field of operation was aseptic. It may be objected that the deeper parts were not aseptic, and that when they were disturbed by the curette and the large vein in the dura wounded, a dose of poison was instilled, which caused the meningitis ; while the continuation of the curetting and cleansing afterwards removed the local extra-dural sepsis. He admitted that it was practically impossible to render the deeper parts of a carious bone cavity aseptic without curetting it. If it were possible there would be no need to operate.

On the other hand, the rapid onset of convulsions, the symmetrical distribution of the œdema over the convexity of both frontal lobes, the thickness of the membranes affected, the absence of changes in the tissues over the temporal bone and base of the brain, all seem to him to favour the idea that there had been a latent meningitis, which was lit up by the depressing effects of the anæsthetic and operation, and possibly a fresh dose of toxine in the blood.

During the week which followed the conclusion of this case—a somewhat marasmic child, seven months old, with facial paralysis and suppurative otitis media, was brought to him for operation. He advised temporising while a preliminary course of antiseptic treatment was carried out. No operation was therefore performed, but the child died next day.

Unfortunately no post-mortem examination was allowed to be made, and the symptoms as reported to him did not point out the cause of death.

He naturally asked himself whether either or both of these children could have been saved by early operation, and whether either could have been operated on with safety and success at the stage reached when he saw the cases.

For himself, he had formed the opinion that in children under two years of age—owing to (*a*) the possibility of latent meningitis; (*b*) the extreme difficulty of rendering aseptic the deeper parts of the field of operation, when the petrous is involved; (*c*) the softness of the bones, their richness in blood-vessels, lymphatics, and connective tissue; and (*d*) the ease with which convulsions are excited in young children, it is wiser not to undertake a curetting operation except at a comparatively early stage of the bone disease, or when the children appear to be in other respects in good health.

Dr. Milligan said, in regard to Mr. Jones' first case he would like to know whether he had attempted an investigation by puncturing the lumbar theca and analysing the fluid extracted. He understood from reading that a slight difference in its composition indicated whether the abscess was in the brain or whether it was a meningeal affection; the difference was something like one per cent. of albumen. In regard to the second case, had any examination been made of the condition of the ventricular linings?

Dr. Hugh Jones replied. He had not employed lumbar puncture. The diagnosis had not been in doubt in the cases under discussion. No part of the ventricular lining except that of the medulla and pons was preserved for bacteriological examination, and the latter had not yet been cut, but there was no naked-eye appearance of any extension into the ventricles, and the whole process seemed to be confined to the convexities of the frontal lobe.

Dr. Milligan said he asked because he remembered one case in which convulsions were one of the most marked symptoms before death, and it was found at the post-mortem

that the whole of the two lateral ventricles were saturated with hæmorrhages.

Mr. FAGGE said that Dr. JONES had raised the question of the signs and symptoms produced by a latent cerebral abscess. He would suggest the value of a blood count and would regard a marked leucocytosis in the presence of other suggestive symptoms as of great importance.

Mr. HUGH E. JONES, in reply, said that in his second case the question which chiefly interested him was: did the infection take place after the operation, or was it a condition which had been going on for some time? He believed that the meningitis had been present, unrecognised, for a considerable time. With regard to the first case, he had taken the opportunity of expressing his conviction that there must be, in cases of latent brain abscess, clinical signs which, if formulated, might be sufficient to enable the surgeon to arrive at a definite diagnosis. He had pointed out in a paper in the *Transactions* of the last International Otological Congress that occasionally when operating on cases of chronic suppurative otitis we were probably operating in the presence of a latent brain abscess of whose existence we were in ignorance.

Mr. DE SANTI was of opinion that the infection in the second case existed previous to the operation. The general symptoms and the rapidity with which convulsions had manifested themselves (twenty-four hours after operation) pointed to there having been pre-existing infective irritation.

SIXTH ORDINARY MEETING.

HELD AT THE ROYAL COLLEGE OF PHYSICIANS, EDINBURGH,

Saturday, May 11*th*, 1901.

DR. THOMAS BARR, VICE-PRESIDENT, IN THE CHAIR.

The following message from the King was read, Members standing :—

"HOME OFFICE, WHITEHALL,

"*March* 21*st*, 1901.

"GENTLEMEN,

"I am commanded by the King to convey to you hereby his Majesty's thanks for the loyal and dutiful message of the Members of the Otological Society of the United Kingdom expressing their sympathy with his Majesty and the Royal Family on the occasion of the lamented death of her late Majesty Queen Victoria.

"I am,

"Gentlemen,

"Your obedient servant,

"CHARLES T. RITCHIE.

THE HONORARY SECRETARIES OF THE OTOLOGICAL SOCIETY OF THE UNITED KINGDOM,
11 Chandos Street, Cavendish Square.

Mr. Charles A. Ballance opened a discussion on

The operative treatment of abscess when situated in the brain.

Mr. President and Gentlemen,—None of us can have forgotten the beautiful story of "Rab and his Friends." * wherein is painted by a master-hand an operation by your great surgeon, Syme, in the pre-chloroform and pre-antiseptic days. The heartrending description of the operation would be true to this day but for the genius of Simpson, as chloroform—"one of God's best gifts to His suffering children"—might still be unknown. And the "Reaper whose name is Death," † would still be reaping the "bearded grain," by means of the bacillary "sickle keen"—the dread and fatal septic illness that cut off the life of Ailie—had not Lister, the peerless knight of surgery, after long years of toil, vanquished the terror of the surgeon. Truly,

> "We hold him for another Herakles
> Battling with custom, prejudice, disease,
> As once the son of Zeus with Death and Hell." ‡

Indeed, we may detach some words from a sublime passage in which Macaulay immortalises the genius of an illustrious statesman, and say of Lister: "History will deliberately pronounce that among eminent men no one has left a more stainless and none a more splendid name." §

In the city where these greatest benefactors of humanity lived and taught it is indeed a high honour to have been called upon to open a scientific discussion.

On looking over my paper on the journey north I could not help being struck with the contrast between even a practical paper and the triumphant achievements of the Edinburgh

* By John Brown, M.D.
† Longfellow, "The Reaper and the Flowers."
‡ W. E. Henley, A Book of Verses, "The Chief."
§ Essay on "The Earl of Chatham."

school. The exclamation of Tony Lumpkin when Diggory handed him a letter came to my mind:

"A damned cramp piece of penmanship as ever I saw in my life." *

"The greatest trust between man and man," writes Lord Bacon in his essay on Counsel, "is the trust of giving counsel." We have it on the authority of his greater contemporary that

"Some men have greatness thrust upon them." †

This is my fate, for to offer counsel on the subject of the treatment of abscess of the brain presents transcendent difficulty, and to be requested so to do implies a trust in my ability which I am only too conscious will fall short of the standard set before me. In fact, not to put too fine a point upon it, I somewhat fear my fate may be comparable to that of Metis,‡ whose name, Bacon tells us, signifies counsel. It was her fate to be married to Jupiter, who, as soon as she conceived, ate her up lest he might be deprived of any of her counsel. I do not imagine that the members present will appraise my counsel so highly that they will be anxious to follow the lead of Jupiter, but should that consummation happen it is my fervent prayer that they may partake of a spiritual rather than of a corporeal feast.

Macbeth tells us—

"The time has been
That when the brains were out the man would die,
And there an end."§

Though this dire calamity frequently dogs our footsteps, yet the times have changed, for now the Society's "great consult begins,"‖ not, as in Milton's Stygian Council, held at Pandemonium, by the passing of "resolutions in despair,"¶ but

* Goldsmith, "She Stoops to Conquer," act iv. line 388.
† "Twelfth Night," act iii. scene 4, line 43.
‡ Essay on "Counsel."
§ Act iii. scene 4, line 78.
‖ "Paradise Lost," book i. line 798.
¶ *Ibid.* book i. line 190.

having gained "reinforcement of hope" from past success, we—

> " . . . meanwhile revive,
> Abandon fear, to strength and counsel joined
> Think nothing hard, much less to be despaired." *

"Things unattempted yet"† the advance of knowledge will make possible, the tide of Truth is ever flowing.

> "For while the tired waves, vainly breaking,
> Seem here no painful inch to gain,
> Far back, through creeks and inlets making,
> Come silent, flooding in the main." ‡

So it has been in the advance of surgery. Only by slow degrees has problem after problem been grappled with and solved. One of the latest triumphs of the art of the chirurgeon is shown in the operative treatment of abscess of the brain. In a steadily increasing number of instances it can truly be said of the surgeon :—

> " . . . strangely visited people
> All swoln and ulcerous, pitiful [in the brains],
> The mere despair of surgery, he cures." §

Although in the surgical treatment of disease of the brain we are as yet only on the threshold of success, nevertheless the near approach of a perfect understanding of these matters may be confidently predicted. Then will it be possible to enter into the thought of the Roman poet :

> "No pleasure is comparable to the standing upon the vantage ground of truth [a hill not to be commanded, and where the air is always clear and serene] and to see the errors, and wanderings, and mists, and tempests in the vale below." ||

"The more I think of it," says Ruskin, "I find this conclusion more impressed upon me—that the greatest thing a human soul ever does in this world is to *see* something and tell what

* "Paradise Lost," book vi. line 493.
† *Ibid*, book i. line 16.
‡ Poem by A. H. Clough, "Say not the struggle nought availeth."
§ "Macbeth," act iv. scene 3, line 150.
|| Lucretius ; see Bacon's Essay on "Truth."

it *saw* in a *plain* way." In this paper an attempt is made to tell in a *plain* way a few of the things which I see with regard to abscess of the brain. "Whether these seeings are there at all is another matter." The object in view is to induce my colleagues and fellow workers to tell also what they have seen. "The practical bearings of our theme" are of incalculable interest to science and to man. Correct observation is the vital "thread which binds the facts" and widens the field of knowledge.

General considerations.—Before describing the exact details which must be carried out in the operative treatment of abscess of the brain certain general considerations demand attention. An abscess of the brain is situated in a tissue of "liquid texture."* This tissue, containing little less water than the blood and enclosed in an inextensile bony capsule, is subject to the laws of hydrostatics. The integrity of certain parts of it is essential to the continuance of life. Placed within the cranium, the abscess is, until exposed by operation, quite beyond the reach of physical examination. Important facts, therefore, readily ascertainable by this method with reference to an abscess in an accessible situation are not at the command of the surgeon when he has to operate for the relief of brain abscess. Despite the dictum of the poet that—

> "'Tis the blot upon the brain
> That *will* show itself without," †

the objective and subjective symptoms upon which the diagnosis is made point to a lesion of the cerebral substance but do not indicate clearly its nature and extent. The surgeon has to operate without any certain knowledge as to the size of the abscess and the acuteness of the inflammation, nor can he often truly surmise whether he has to deal with circumscribed or diffuse suppuration or both. Even when the history seems to point clearly to an acute condition it may be found that the abscess is of old standing. Abscess

* "Paradise Lost," book vi. line 348.
† Tennyson's "Maud," part ii. iv. 8.

in the brain may be latent, producing only general symptoms of ill-health, until excited to renewed activity by a febrile attack, by a blow on the head, or by some minor operation, such as the removal of a polypus. By a latent brain abscess. then, is meant one producing no symptoms directly referable to a lesion of the brain. Such an abscess is, in all parts of the body, enclosed in a capsule. An abscess producing slight symptoms over a considerable period of time may not be encapsuled. This is true of the brain as of the neck or any other region. This variety of abscess has a tendency to extend, causing local destruction of tissue. A history of long-continued cerebral symptoms does not necessarily point to the presence of a capsule around the area of suppuration, for in a case of cerebellar abscess with symptoms dating back at least eight months no capsule was found, but the whole cerebellar hemisphere was nothing but a shell of softened grey matter.* The two conditions of acute abscess and old encapsuled abscess may exist together, as in a case that occurred to one of my colleagues, now deceased, in which an acute cerebellar abscess was opened with relief to the symptoms, but at the necropsy an old encapsuled abscess was found internal to that which had been opened.† I have drawn attention to several such instances. ‡

The question must now be asked, How is an abscess of the brain to be treated? There can be no discussion as to the nature of the reply. Stäcke§ says: "Otology is an offshoot of surgery, and only in close adherence to it and in the true and conscientious observance of its principles is success to be sought for and to be found. The most important principle is the care for free, unhindered, spontaneous drainage." These significant words were written in reference to the treatment of middle-ear suppuration, and they apply with equal force to the treatment of abscess of the brain, which is the only too

* Allbutt's "System of Medicine," vol. vii. p. 590.

† *St. Thomas's Hospital Reports*, vol. xxiii. p. 208.

‡ *St. Thomas's Hospital Reports*, vol. xxiii. "Cases of Cerebellar Abscess," by T. D. Acland and C. A. Ballance.

§ *Berliner Klinische Wochenschrift*, 1889.

frequent result of failure to comply with them. Success can be won only by close attention to those fundamental surgical principles which guide us in the treatment of abscess elsewhere. In one of the most recent text-books on surgery* we find these principles thus tersely stated: "In the treatment of an abscess there is one absolute rule which knows no exception, viz., that whenever and wherever pus is found the abscess should be evacuated at once, and after evacuating it thorough drainage must be provided for." To which may be added that when a purulent collection is encapsuled enucleation is the proper treatment. In the great majority of abscesses in the brain, as elsewhere, there is no capsule. The following is, however, an instance in which a capsule one-eighth of an inch thick was present, but owing to a mistake in diagnosis the abscess was not removed.

A man, aged 40 years, was admitted to hospital on Sept. 14th, 1895, with severe occipital pain, vomiting, and slow cerebration. He had paralysis of the right sixth nerve and double optic neuritis. He lay on his right side in bed. There were forced movements to the right and rotation to the right in walking. With the eyes shut he fell backwards and to the right. In the beginning of May in the same year he had a severe illness with shivering, sweating, and rigor, said to have been of influenzal origin. This had been followed by slight loss of power on the left side, from which he had recovered. About ten days before admission the headache and other symptoms returned. On the day following admission (Sept. 15th) a rigor occurred at 5.30 P.M.; at 6.30 coma was complete; at 7.30 artificial respiration was necessary and was continued until I arrived. I was told that the case was thought by the physician to be one of cerebellar tumour. Considering it almost impracticable to remove a cerebellar tumour during the performance of artificial respiration, and thinking that the left-sided paresis might be due to involvement of the right cerebral hemisphere, I removed a large area of bone over the right motor cortex. The brain bulged under great pressure, but natural respiration did not return.

* Da Costa, "Modern Surgery."

A trocar sheathed with a cannula was plunged in up to the hilt and impinged upon a hard mass into which it would not penetrate. As this was thought to be a solid basal tumour which could not be removed the operation was abandoned. The necropsy revealed an encapsuled abscess containing an ounce of thick greenish pus, replacing the right optic thalamus. The capsule was very firm and quite one-eighth of an inch thick. This abscess might have been enucleated had it been recognised.

When there is no capsule the treatment is free incision and drainage, but the provision of drainage is more difficult in the brain than in other more solid tissues where, by free incision and counter-opening, it is easy to establish drainage and effect a cure. The difficulty is that in the "liquid texture" of the brain as soon as the abscess is opened, the intracranial pressure causes the fluid brain substance surrounding the abscess to flow towards the surface, so that a large portion of the cavity of an unencapsuled abscess is at once shut off from communication with the incision.

Since micro-organisms behave in the brain as they do elsewhere in the body, the question naturally arises, Should the bacteriology of the abscess modify the treatment? It has been already pointed out that until the brain has been entered it cannot be discovered whether the abscess is localised or is spreading. The virulence of manifest suppuration presents clinical features which indicate its bacteriology to the mind of the surgeon who has had some training in that subject. These clinical signs cannot be observed in the case of brain abscess, but it is nevertheless supremely important to determine the nature of the micro-organism at the earliest possible moment, as the use of a suitable antitoxin may prove to be a valuable weapon in the fight against death.

Details of operation.—We now proceed to consider step by step how the surgical principles of the treatment of abscess are to be carried on in the case of the brain. It is taken for granted that the local source of infection has been thoroughly removed. The abscess must now be exposed by an appropriate operation, the steps of which are the following:—

1. *Sterilisation of the skin.*—Shave the scalp, scrub it with ethereal soap and sterilised water, wash the soap away with sterilised water, rub firmly with turpentine on a sterile swab and then again with ether. If the operation is not to be done immediately, apply sterilised lint soaked in a glycerine solution of perchloride of mercury (1 in 1000). If the operation is proceeded with at once, swab the skin with strong carbolic or perchloride lotion. The hands of the operator and his assistants must in like manner be cleansed and then immersed in an alcoholic solution of perchloride or biniodide or the glycerine perchloride solution. The wearing of sterilised gloves is also recommended.

2. *Anæsthesia.*—The anæsthetic should be chloroform, and it should be given warily, for, especially in cases of cerebellar abscess, respiration is apt to cease. On two occasions it has happened in my experience that with the first few inhalations of chloroform respiration ceased and the operation had to be completed during the performance of artificial respiration. Neither morphia nor strychnia should be administered before the dura has been opened.

3. *Incision of the scalp.*—A flap is to be preferred to a crucial incision. It should be cut with its base downwards and should be considerably larger than the opening designed to be made in the skull.

4. *Opening of the bone.*—I am convinced that failure may result from neglect of the rule of surgery to make a free opening. How can a *free* opening into the abscess be effected through an inadequate opening in the bone?

> "Wounds by wider wounds are healed,
> And poisons by themselves expelled." *

The trephine employed should be five-eighths of an inch in diameter, of slightly conical shape, and should have the teeth outside. (*a*) In temporo-sphenoidal abscess the site of application of the point of the trephine should be about seven-eighths of an inch above the suprameatal spine, the object being to expose the lowest part of the middle fossa

* Butler, "Hudibras."

just external to the tegmen antri and tegmen tympani. Immediately above these tegmina are the tissues in which, as a rule, the infective process first develops. When the disc of bone has been removed by the trephine more bone should be cut away with small saws, forceps, or Cryer's drill, until the opening in the skull is enlarged to a parallelogram measuring one and three-quarter inches antero-posteriorly and one inch vertically. The lower edge of the parallelogram is marked by that of the trephine opening. Three-quarters of an inch of its antero-posterior extent should lie behind the centre of this aperture and one inch in front. The lowest part of any abscess in the temporo-sphenoidal lobe can be efficiently drained through this opening, and the bone disease (usually the tegmina) which is the source of infection can be directly observed and removed. I have known a case where a temporo-sphenoidal abscess was opened at its highest part and where life was saved only by making a counter-opening in the situation here recommended, the man having been for some weeks in a condition of cerebral irritation. If the abscess is above and behind, or above and in front of the opening more bone should be taken away, so as completely to expose the surface of brain which is external to it; or, if the surgeon so prefer, he can make a trephine opening higher up and utilise the lower aperture as a counter-opening. The former method is recommended. (*b*) In operating for cerebellar abscess the same trephine should be used. It should be placed on the bone so that its anterior edge touches the posterior border of the mastoid process. Its upper edge should be just below Reid's base line. In this way the horizontal and vertical portions of the sigmoid sinus are avoided. The opening should be enlarged backwards and downwards until it is quite an inch and a quarter in antero-posterior, and one inch in vertical, extent. The opening may require enlargement, especially in cases where the abscess extends into the posterior part of the lateral lobe. It cannot be carried forwards with much advantage, as the vertical portion of the sinus is in the way of incision of the dura in this direction. It is to be remembered especially

that the removal of bone, while comparatively easy before incision of the dura mater, is not so satisfactorily accomplished when that membrane has been incised and the brain is bulging under pressure.

5. *Incision of the dura mater.*—Here, again, a flap is preferable to a crucial incision. A small aperture should be made with a knife, and the flap (having its base sideways or even upwards)* should then be cut with fine, blunt-pointed scissors. Great care must be taken to avoid wounding the vessels of the cortex which are forced by the intracranial pressure into close contact with the membrane.

6. *Discovery and incision of the abscess.*—When there is a sufficient opening in the bone it may be possible to determine by palpation that the abscess is immediately sub-cortical. An incision should at once be made through the intervening portion of brain substance into the abscess cavity, care being taken to avoid wounding the vessels as in other parts of the body. The use of a trocar and cannula, a pus-seeker, or other special instrument, is unnecessary and contrary to surgical principles. If the site of abscess is not obvious, it must be sought for by exploratory puncture, and, in so doing, it should be remembered that the site of the abscess is almost certainly close to the bone disease which gave rise to it. The best instrument to use is a sharp-pointed, long, and narrow knife. Our brains are not like Satan's—

> "Entrails, heart, or head, liver or reins," †

which Milton tells us could

> "Not in their liquid texture mortal wound
> Receive, no more than can the fluid air";

and a wound made by the surgeon's knife will not heal quite so readily as that inflicted by the sword of Michael; yet in the brain, as elsewhere, clean-cut wounds heal more readily than any others, and there is certainly less risk of the abscess being missed when search is made for it with a sharp knife

* Suggested to me by Dr. C. D. Green.

† "Paradise Lost," book vi. line 346.

than when any other instrument is employed. There have been cases of (1) trocar and cannula missing the abscess; of (2) trocar and cannula passing through the abscess without tapping it; and of (3) trocar and cannula striking the abscess but failing to penetrate its capsule (as in case described on p. 8). The following is a striking example of trocar and cannula failing to evacuate a large abscess. "The brain was explored in various directions with a trocar and cannula" with a negative result. At the necropsy there was found "a large abscess with very thick walls containing over four ounces of green, offensive pus. So thick was the wall that the abscess shelled out whole and could be rolled about the table. In fact, it needed a sharp plunge with the knife to open it."*

The use of the knife for the evacuation of an abscess of the brain is not a new operation, but was taught and practised more than a century ago. Dupuytren† in one of his lectures says: "In certain cases of deeply seated fluid collections we must incise the dura mater, the arachnoid, the brain itself, if the focus is at the surface of this organ, and by this bold proceeding patients have been saved." A little farther on in the same lecture he continues: "Relying also on the success of J. L. Petit, Boyer concurs in the advice of Quesnay and does not fear to plunge the bistoury quite deeply (*assez profondement*) into the very substance of the brain in order to evacuate traumatic effusions which may have formed there, and it has fallen to my lot to do so several times with success." Like many another step in the advance of knowledge, this advice, though justified by some brilliant successes, remained for a considerable time a dead letter, for we find a great English surgeon writing nearly half a century later: "There are few surgeons who would have the hardihood of Dupuytren, who plunged a bistoury into the substance of the brain and thus luckily relieved the patient of an abscess in this situation."‡ And after yet another decade the famous

* Abbott, *St. Thomas's Hospital Reports*, vol. xxv., p. 205.

† "Leçon's Orales," second edition, vol. vi. pp. 183–4 (published 1839, date of lecture not given).

‡ Erichsen's "Surgery," seventh edition, 1877, vol. i. p. 532.

case of Dupuytren is thus alluded to in a later edition of the same work: "This was doubtless a somewhat rash thing to do without previously ascertaining the presence of pus by milder means."* Dupuytren, in his account of this historical case, says simply: "I incised the dura mater, nothing came out; I thrust a bistoury cautiously" (? so as to avoid the vessels of the cortex) "into the brain, and there welled up immediately a flood of pus. That very night all the symptoms disappeared and the patient recovered."† If careful exploratory puncture with the knife fail to find the abscess, the finger inserted into the brain substance will almost infallibly detect the presence of a tense abnormal swelling. Mistakes, however, may still be made, as is illustrated by two cases related in my article on "Certain Affections of the Ear" in Clifford Allbutt's "System of Medicine." In one of these, one cerebellar abscess and, in the other, two had been opened, yet both patients died from an unopened abscess, oyster-like in shape, lying immediately beneath the cortex of the upper surface of the cerebellar hemisphere. The examining finger felt the sensation of resistance, but this was attributed to the tentorium.

7. *The further treatment of the abscess.*—When the cavity is not entirely closed by the waves of brain substance it may be gently irrigated with a weak antiseptic; but on no account should this be done unless two drainage-tubes are so arranged as to ensure the free escape of the fluid. Sterilised normal saline solution is recommended; but I am not in favour of irrigation except in very exceptional and chronic cases. Unless the opening in the cortex is large, I am opposed to the tamponing or packing of the cavity with gauze, because the tampon tends to obstruct the free exit of septic material. In one case of abscess of the temporo-sphenoidal lobe in which I removed a large area of bone, I ligatured and removed the cortex corresponding to the outer boundary of the abscess. The inner wall of the abscess, which was at first treated by gauze plugging, soon came to form part of the outer surface

* Erichsen's "Surgery," ninth edition, 1888, vol. i. p. 781.

† "Leçons Orales," *loc. cit.*, p. 146.

of the brain, and was thus directly accessible for dressing. Complete recovery ensued.

As to drainage-tubes, the rules for their use in abscess of the brain do not differ in any way from those which apply to their employment in the healing of suppurating areas elsewhere. When a tube has been successfully introduced it should not be disturbed for some time. The most successful cases treated in this way are those in which the tube remains undisturbed for many days. Tubes are shortened or removed only as the cavity heals from the bottom. The nature of the tube is of little consequence. All tubes are liable to become blocked with brain *débris*.

In the case of a small abscess deeply placed in the anterior and inner portion of the cerebellar hemisphere, the surgeon may be unwilling to use the knife for evacuation. Recourse must then be had to the exploring trocar and cannula, the latter having rings of wire attached by which, when it has penetrated the abscess, it may be immediately fixed to the scalp by silkworm gut. Many a case has been lost after the pus has been evacuated, owing to failure to re-introduce the tube in the proper position. The trocar and cannula should be of platinised silver. In the event of a counter-opening being made, or of drainage occurring, in consequence of disease or of operative interference, *viâ* the region of the tegmina, gentle irrigation through the diseased area of brain may be beneficial, just as it is in cases of abscess with a counter-opening elsewhere.

8. *Closure of the wound and dressing.*—An aperture is now made in the base of the flap of the size of the opening in the brain, and the edge of the flap is replaced in position and sutured with fine silkworm gut. In certain cases it is not advisable to replace the flap. A powder may be used for dusting around the wound, but it should be sterilised. The dressing may be of sterilised cyanide gauze, either used dry or wrung out of carbolic lotion (1 in 40). A dry sterilised cyanide dressing is recommended, and the bandage should, if possible, be so managed as not to cover the forehead.

9. *After-treatment.*—This is a matter demanding the close personal attention of the operator. The dressing may require to be changed daily or not at all, according to the nature of the disease and the condition of the wound. (1) The primæ viæ should be kept open by the administration of some preparation of mercury. I have found, too, in septic cases that the pill of colocynth and hyoscyamus is very efficient in clearing the intestine of foul-smelling fæces. (2) In regard to food it may be noted that barley-water and beef-tea are often borne by the stomach when milk is rejected. (3) As to alcohol, in certain cases we can hardly do without it. When it must be given I personally prefer to order old brandy, though in this city old Scotch whisky would, no doubt, be selected. Far be it from me to assent to the "startling question" of the gifted Calverley* that both the ancient Greeks and the Scotch ought to have invented and adhered to another beverage.

> "The Greek mind must have had some vital fault,
> That they should stick to liquors so injurious
> (Wine, water, tempered p'raps with Attic salt)—
> And not at once invent that mild, luxurious,
> And artful beverage, Beer. . . .
> Then nectar—was that beer, or whisky-toddy?
> Some say the Gaelic mixture, *I* the Saxon:
> I think a strict adherence to the latter
> Might make some Scots less pigheaded, and fatter."

(4) Hernia cerebri is an evidence of sepsis. It is best treated by sterilised antiseptic dressings. To prevent the dressing from adhering to the hernia some form of protective should be used—perhaps gold leaf is the best; slight elastic pressure is useful in the later stages of the treatment.

10. *Recurrence of symptoms.*—It is by no means uncommon to have a return of symptoms a few days after the evacuation of the abscess, due either to the refilling of the abscess cavity from faulty drainage or to the formation of a new abscess in another part of the same lobe. In the cerebellum it is by no means infrequent to have a second or even a third abscess. Instead of concentrating the attention on the original site of

* Verses and Translations. "Beer," by C. S. C.

abscess the new symptoms, such as high temperature, rapid irregular pulse, screaming fits, retraction of head, general twitchings, vomiting, drowsiness, etc., may suggest conditions such as meningitis or acute distension of the ventricles which are not present. The surgeon,

> "Vext with waste dreams," *

and led astray by these speculations, may fail to act wisely. We may perhaps apply the words of Goethe†:—

> "I tell you what; your speculative wretch
> Is like a beast upon a barren waste,
> Round ever round by an evil spirit chased,
> Whilst all about him fair green pastures stretch."

Your great countryman, Carlyle, has said: "Genius is the transcendent capacity for taking trouble first of all." And Joubert has written: "Genius begins great works, labour alone finishes them." Both of these maxims are eminently true of the treatment of abscess of the brain. In order to succeed, the surgeon must "take trouble first of all" in weighing well every point in the history and symptoms of the case and in planning and executing the operation with minute attention to every detail. And in order to finish his "great work" he must spare neither labour nor time in watching the progress of the case and in personally carrying out all the minutiæ of the after-treatment. Many are the vicissitudes of the days and weeks that follow the operation. To be able to choose with certainty and to carry out with precision the various measures which make for success and oppose a disastrous termination, the surgeon must have at his command an exact knowledge of the significance of the various symptoms that arise and of the resources and methods available for their systematic treatment. The surgeon cannot here delegate his duties or shift his responsibility, and amid the difficulties that beset him in combating the disease he

* Tennyson, "Idylls of the King," "The Coming of Arthur."

† "Faust," act ii. scene 4 (Sir T. Martin's translation).

may well utter the prayer which the veterans of Frederick the Great sang as they marched to meet the foe at the battle of Leuthen—

> "Grant that with zeal and skill this day I do
> What me to do behoves, what thou command'st me to;
> Grant that I do it sharp, at point of moment fit,
> And when I do it grant me good success in it." *

And when the case has been brought safely through all difficulties and dangers into the smooth water of convalescence we may well say of the surgeon who saves his patient as Bunyan † did of his victorious pilgrim:—

> "Hob-goblin nor foul fiend
> Can daunt his spirit;
> He knows he at the end
> Shall life inherit!
> Then fancies fly away,
> He'll fear not what men say;
> He'll labour night and day"
> [To save his patient].

In conclusion, allow me to say how well I know the toughness of the problem which the surgeon has to face in coming to a decision to operate in certain cases suspected of harbouring an abscess of the brain. The advice given to Richard Plantagenet is much to the point:—

> "But yet be wary in thy studious care." ‡

Delay as the result of consultation may be disastrous, "for occasion turneth a bald noddle after she hath presented her locks in front and no hold taken"; § and "the ripeness or unripeness of the occasion must ever be well weighed." ‖ On the one hand, boldness alone is "ill in counsel, good in execution"; ¶ on the other hand, "it is a dangerous thing to trace the thread of knowledge a little way and fancy we have found the end." ** What is required in consultation is

* Carlyle's translation. *See* "History of Frederick the Great," book xviii. chapter x. † "The Pilgrim's Progress," part ii.

‡ Henry VI., part i. act ii. scene 6, line 97.

§ Bacon's Essays, "Of Delays." ‖ *Ibid.*

¶ Bacon's Essays, "Of Boldness."

** A. W. Holmes-Forbes, "The Science of Beauty," p. 195.

knowledge, experience, a grave sense of responsibility, and the strength to accept the consequences arising therefrom; indeed, to fulfil the Pauline exhortation, "Be strong—quit yourselves like men."* When the decision to operate is made it should be acted upon at once; hesitation or delay may be fatal. A patient suffering from cerebellar abscess has died in the night, the operation having been arranged for the following day—"True despatch is a rich thing."† "Yet and but," said the Templar, "are words for fools; wise men neither hesitate nor retract, they resolve and they execute."‡

But still, in spite of all our care and pains, success may be wooed in vain. There may be no abscess or, if present, it may not be found.

> "The best laid schemes o' mice an' men
> Gang aft agley,
> An' lea'e us nought but grief an' pain
> For promis'd joy." §

"The smallest actual good," says Macaulay, "is better than the most magnificent promises of impossibilities"; and the stay of the surgeon in the midst of depression, discouragement, and defeat is the consciousness that he has "faithfully rendered an unrewarded obedience to the command"|| of the Preacher.¶

> "The man who though his fights be all defeats
> Still fights
> Enters at last
> The heavenly Jerusalem's rejoicing streets." **

> "In earthly races
> To victors only do the heralds call;
> But, oh! in yonder high and heavenly places
> Success is nothing *and the work is all.*" ††

Yet, kindled by the past, the surgeon may surely say, "I

* 1 Cor. xvi. 13; 1 Sam. iv. 9.
† Bacon's Essay, "Of Despatch."
‡ "The Talisman, chapter xix. § Burns, "To a Mouse," verse 7.
|| Ruskin, "Sesame and Lilies," lecture iii.
¶ Ecclesiastes ix. 10.
** C. Patmore, "The Unknown Eros," "Victory in Defeat."
†† Quoted from a biographical sketch of Sir William Gull.

shall arrive." "The succession cannot break. The further evolution must go on . . . first the blade, where we are to-day; then the ear, where we shall be to-morrow; then the full corn in the ear, which awaits our children's children, and which we live to hasten."*

Dr. BARR.—I am sure, gentlemen, you will agree with me when I say that from a literary and scientific as well as from a practical point of view this has been a most admirable address.

An address such as this from one who is not only conversant with the subject of otology but is also an expert general surgeon has peculiar value.

It is a subject in connection with which we otologists may very properly sit at the feet of the general surgeon and learn, as we have done to-day, valuable and practical lessons. Many of us still consider it our duty to call in the aid of the general surgeon, although probably the time is rapidly approaching, when every otologist will regard these intracranial operations as within the sphere of his practice.

While this subject is of great interest to the otologist, perhaps the general surgeon is the one whose views are those which we may desire to hear in the first place; we shall be glad, however, to hear the opinions of any one present.

It has been arranged that the limit of time for each speaker will be ten minutes.

Dr. MCBRIDE.—I was delighted to hear that Mr. BALLANCE laid stress on the point of opening temporo-sphenoidal abscesses low down if possible. This was a principle that Mr. MILLAR and I insisted on in 1886. I see that the German School have gone a stage further and are opening many temporo-sphenoidal abscesses by an extension of the radical operation by removing the tegmen tympanum. One of the great troubles with regard to operating on cerebral abscesses seems to me the difficulty in diagnosis. When is one entitled to operate? I lately had an interesting

* "The Ascent of Man," chap. x., by H. Drummond.

case in which I had to trephine myself, because a general surgeon was not available. This was a patient who came into my ward on October 16th, complaining of discharge from the ear. When seen in the waiting-room I found carious bone, and admitted her with the view of removing this bone. After she came in she began to be sick. I operated next day and removed two large sequestra. The temperature fluctuated between 97° and 98·4° F. The kidneys, lungs, and heart were normal. The respirations were somewhat quickened. The next morning there was nothing apart from sickness to indicate urgency. The following day she was no better, and was sick. On the third day she was semi-conscious, and on the afternoon of that day she became comatose. I thought that operation should not be delayed longer. I trephined as near the external auditory meatus as possible and exposed the temporo-sphenoidal lobe, but found nothing. I did not feel justified in exploring the cerebellum. She died on the following morning. The pathologist could find nothing. It was a remarkable case, and I am unable to explain it at present.

I must again thank Mr. BALLANCE for his most excellent address, for which we are the wiser in literature and philosophy as well as in things medical.

Dr. PRITCHARD: Mr. President and Gentlemen,—Listening to such a splendid paper as Mr. BALLANCE'S has one great disadvantage to me—it makes me feel so small.

I want to ask one question. I should like to know, as regards drainage, whether Mr. BALLANCE has tried the method recommended by Mr. HORSLEY, viz., using three rubber drainage tubes together, so that one can be withdrawn at a time without disturbing the others, and thus the direction of the sinus is not lost.

As regards what Dr. MCBRIDE was saying, a long time ago I recommended that in operating one should always go from the source of the disease to its results, that is, from the disease in the ear to its results within the cranial cavity.

As a rule I prefer, having opened the antrum, etc., to search for the lateral sinus. This having been exposed in its

horizontal course, the cerebrum can easily be explored above the sinus, and the cerebellum below it. The operation may be modified according to circumstances, but the lateral sinus forms a very valuable guide to start with.

Mr. Dundas Grant: The admiration which Mr. Ballance's paper has inspired, both from the technical and the literary point of view, is what I anticipated. I know what a reader Mr. Ballance is, and I expected nothing else than what we have heard from him.

During the reading of his paper I wrote down several headings: "Fig" abscess, frontal abscess, syringing, drainage, introduction of the finger.

I have had some experience of these. In a case under my care I diagnosed cerebellar abscess. I explored with the trocar and found no pus, though I felt sure pus was present. I explored again, and again found no pus. Unfortunately I only used a large trocar and cannula. At the post-mortem an abscess was found in the cerebellum which was comparable to a small boiled fig. Its capsule was so hard that the trocar did not penetrate it.

In another instance I made a very natural mistake. The case was that of a boy with severe panotitis of both ears. (After death, necrosis of the labyrinth itself was found.) I felt confident that he had either temporo-sphenoidal or cerebellar disease. On exploration on both sides no pus was obtained. The post-mortem examination revealed an abscess in the frontal lobe of the right side.

With regard to the syringing, I am sure that I have seen damage resulting from forcible syringing, and have abandoned it altogether except where there is a very large drainage tube, and then the tip of the syringe has to be held just at the orifice. As regards drainage through the "roof," it is better to have the opening through which you are draining the abscess away from the seat of the radical mastoid operation, unless you are sure that the whole disease has been eradicated and that no infection may be feared.

The use of the drainage-tube depends on what the introduction of the finger teaches you. In a case of temporo-

sphenoidal abscess I introduced a very large drainage-tube, and found it gradually pushed out day after day. In this same case there was an enormous amount of what appeared to be tubercle bacilli. I should like to ask, What is the lesson to be derived from the fact that tubercle bacilli in abundance were found? The patient did extremely well, and is now in very good health. I believe there are cases which have a strong tendency to recover, just as others baffle our efforts. The treatment of these should be in the hands of a surgeon who is *au fait* in the practice of antiseptic surgery.

A *perfect* aural surgeon ought to be able to look at aural disease from the surgical, medical, and otological point of view. Any one man can hardly hope to be perfect in every part, but he should at least be so competent in all, that in urgent cases he will not be found wanting. If he is to be sure of doing as little harm as possible, he cannot too carefully educate himself in the practice of antiseptic or aseptic surgery. Unless he does this he is sure to be a dangerous person.

Mr. SECKER WALKER mentioned the difficulty he had found in satisfactorily draining abscess cavities in the brain, chiefly because the soft walls were forced into the opening perhaps before all the pus had escaped, thus shutting off a small pus collection. In one case of cerebellar abscess, he had to re-open the abscess twice before the result was successful and permanent. He thought Mr. BALLANCE'S suggestion of excision of the external abscess wall would tend to remove this difficulty, and asked for information as to the manner of such incision.

Mr. WALKER disagreed with Dr. DUNDAS GRANT'S suggestion that the aural surgeon should not operate on cases when the disease had extended to the brain. He thought that otologists should be competent to undertake the treatment of diseases of the ear and the complications arising therefrom

Mr. COTTERILL: I am honoured by being called upon to speak at such a meeting as this, and upon a subject in which I am deeply interested.

There are certain points in Mr. BALLANCE'S paper on

which it is possible there may be a diversity of opinion, but I am sure there can be but one opinion as to the value of the paper he has just presented to us.

In what one may call the sanctified atmosphere of an otological meeting, it would be perhaps unwise for a general surgeon to speak strongly as to the advisability or otherwise of the surgical treatment of cerebral abscesses falling into the hands of the otological specialist. I have a strong feeling, I must confess, that the indefinable something which a general operative surgeon collects about him as his experience increases, will in the long run make him the most suitable and reliable person to deal with cases of such great gravity, cases in which complications of the most urgent and alarming nature may occur at a moment's notice, and call for immediate and determined action.

But we may rest content that in the end the treatment of such cases will fall into the hands of the men who are found by experience best equipped to deal with them.

With regard to the opening made in the skull for the detection and evacuation of pus, it has been suggested that the best way to approach these abscesses when their position is indefinite, is to trephine over the temporo-sphenoidal lobe at first, and failing to find the abscess in that position, to prolong the incision in the bone backwards and downwards so as to explore the cerebellum through the same opening in the skull. This appears to me to be likely to prove disastrous, by admitting pus from a cerebellar abscess into the healthy temporo-sphenoidal area; and I believe the method to be wrong. The first incision over the temporo-sphenoidal lobe should, if no pus be found there, be carefully sutured and collodionised, and a separate trephine opening made over the cerebellum.

A fairly large opening in the skull is necessary for the purpose of effectually draining an abscess of the brain. I prefer two drainage-tubes of considerable size: the abscess should not be syringed out.

I show a trephine which is a modification of, and, as I believe, an improvement on, those in common use. It is composed of only two pieces, has no sharp angles to harbour dirt, can be easily sterilised, and has the merit of extreme simplicity.

I am a strong unbeliever in the adequacy of an exploring needle for finding an abscess. I have often failed to find pus with such an instrument when incision into the brain substance, followed by the careful introduction of the finger, has demonstrated the presence of matter; and the finger, when once in the abscess cavity, should not be removed till a drainage-tube has been passed along it into the cavity.

I have lately had two cases of cerebellar abscess under my care, where respiration entirely ceased as the result of the inhalation of chloroform, the operation being concluded under artificial respiration. In such circumstances the operation becomes one of extreme difficulty.

My views with regard to hernia cerebri are not in accord with those still to be found in many of the text-books, where such means for dealing with the hernia as shaving it off, dusting it with astringents, or applying pressure, are recommended. Hernia cerebri is merely an evidence of intracranial pressure, and I cannot agree with Mr. Ballance that it is necessarily an evidence of sepsis. The proper treatment for hernia cerebri is, when possible, to remove this intracranial pressure by the evacuation of pus or the removal of a tumour, and so forth; and if that be impossible, enlarge the opening in the skull and dura and allow the hernia to protrude freely. If the intracranial pressure become subsequently lessened, as, for example, by the absorption of inflammatory material, the hernia will subside and return into the cranial cavity.

Mr. Stiles: I can only echo the words of the previous speaker in admiration of the address we have just listened to. As was to be anticipated, Mr. Ballance, a general surgeon who has done much to advance our knowledge of the intracranial complications of middle-ear disease, endeavours as far as possible to treat abscesses of the brain on the

broad, general principles which govern the treatment of abscesses elsewhere. I have listened to his able paper with great interest, and I do not think I have heard a single word which is open to adverse criticism. I was especially interested in his remarks upon encysted cerebral abscess, as I have had no experience of those cases.

He has struck the keynote as regards treatment of abscesses of the brain, in pointing out the difficulty and importance of maintaining free drainage. I hardly gather, however, as some of the previous speakers appear to have done, that he goes so far as to advocate the removal of the outer wall of the abscess in all cases. Each case, I presume, must be judged on its own merits. But, after all, the difficulties connected with the treatment of brain abscesses rest rather with the diagnosis, and any difference of opinion will be in reference to the course to be adopted and the best route to be taken in order to find and evacuate the abscess. If, after opening up the middle ear, and possibly also exposing and exploring the lateral sinus, enough disease is not revealed to account for the symptoms, and if there is a possibility of the existence of a temporo-sphenoidal or cerebellar abscess, the question arises as to the next procedure to be adopted. In regard to a possible temporo-sphenoidal abscess, it becomes a question as to whether the pus be sought for by removing the attic, or whether the temporo-sphenoidal lobe should be exposed either by enlarging the original opening in the bone or by making a separate trephine opening. Here again it is difficult to lay down any definite rule, and each case must be treated on its own merits.

I was glad to hear Mr. Ballance's remarks upon hernia cerebri, and am quite prepared to agree with him that *progressive* hernia cerebri means sepsis. The qualification "progressive" seems necessary, as it is well known that hernia cerebri frequently occurs apart altogether from sepsis. I have recently operated on a boy suffering from hemiplegia, the result of "idiopathic" intracerebral hæmorrhage, which had ruptured into the lateral ventricle. About a tablespoonful of clot was removed from the ventricle.

A large hernia cerebri developed, but gradually receded. The wound was now quite healed, and the patient was quite well, except for some paralysis of the forearm and hand. There was no sepsis in this case.

As a contrast to the above case Mr. STILES mentioned the case of a girl who suffered from a traumatic cerebral abscess at the site of an old compound fracture of the skull. After opening the abscess a *progressive* hernia cerebri developed. At the post-mortem two other smaller cerebral abscesses were discovered in the occipital lobe, far removed from the original abscess.

Dr. LOGAN TURNER: I have here one or two preparations which may interest the members. For these I am indebted to Drs. WELSH and FLEMING, Pathologists to the Royal Infirmary.

The first illustrates an abscess in the left temporo-sphenoidal lobe, which lies in the lower part of the lobe immediately above the roof of the antrum. The second, while not connected with our discussion to-day, shows a large abscess in the left frontal lobe, which occurred in a case of general pyæmia. It is an example of a non-encapsuled abscess, which Mr. BALLANCE has referred to. The third preparation is a portion of bone removed from the skull six months after the operation of trephining. It shows the aperture in the bone filled up by a strong periosteal membrane.

I should like to refer to the following points in connection with the opening of cerebral abscess after the radical mastoid operation. In a recent paper written by Hammerschlag, 170 cases of cerebral abscess are recorded. Of these, 106 were opened through the squamous temporal, and 40, or 37 per cent. recovered, while 64 were explored through the tegmen tympani, and 31, or 48 per cent. recovered. These figures point to the fact that temporo-sphenoidal abscess can be satisfactorily dealt with through the mastoid process.

Dr. NICOLL: First of all I have to thank the Society for the kind invitation to take part in the discussion. I have enjoyed myself so much as a listener that it is with some reluctance I intervene as a speaker.

There are, however, one or two points to which I should like to refer; and on several of these my opinions differ somewhat from those expressed by Mr. BALLANCE.

(1) In the first place, I am impressed with the advantages of the route into the interior offered by the mastoid cavity—opened out and cleared by a preliminary radical operation, and subjected to thorough sterilising measures.

In dealing with cerebral and cerebellar abscess, as in other matters, the golden rule holds—"First catch your hare." The temporo-sphenoidal lobe and cerebellum, in which such abscesses occur, are amongst the more or less silent areas of the brain. No doubt symptoms, more or less significant, may occur. Yet, in the majority of the cases no *localising* evidence is present. There are present the *general* symptoms of intracranial mischief. All that these symptoms suggest, however, is that the game is lurking *somewhere* in the interior. It seems to me that the easy and natural way of finding the game is to get upon the track. That track starts in the middle ear, and its trail is frequently to be found in the course of a mastoidectomy in the form of a thin track of pus, or granulation tissue, or cario-necrosis extending to the interior through the bone, or of "anchoring" of the brain and membranes to the internal aspect of the bone. To state this to an Otological Society savours of the talking of platitudes. But it would appear that all general surgeons are not impressed with the advisability of seeking for this "lead," and taking advantage of it in finding the intracranial focus.

(2) Similarly, in the evacuation and drainage of the abscess I think general surgeons do not all appreciate the advantages of making use of that track. For example, take an abscess in the temporo-sphenoidal lobe. On the one hand open it by trephining through the squamous bone: you spill pus into the open membranes, and in a certain number of cases lose, in consequence, your patient from meningitis. Or, explore cerebellum, sinus, and temporo-sphenoidal lobe through a common opening made by placing the trephine over the lateral sinus: possibly you wound the sinus with the

trephine. You then explore the cerebellum, as, in the particular case, appearing the most likely region. Finally, you explore the temporo-sphenoidal lobe and find the abscess: the pus spills into the opened, and previously healthy, cerebellar fossa, and into the sinus, if this has been wounded.

On the other hand, work your way into the temporo-sphenoidal abscess through the roof of the mastoid cavity. If you are fortunate you find a "lead" in the shape of a track in the bone, with the membranes and brain anchored to its inner end, and you evacuate the pus through membranes "soldered" off by adhesions, and through tissues already immune to the action of pyogenic toxines. If, unfortunately, no track or anchoring is found you fall back on the route through the squamous bone.

(3) The risk of setting up meningitis during the evacuation of a cerebral abscess. I have become impressed with the magnitude of that risk, and, in order to avoid it, am in the habit of making use of one or other of two principles. First, if the symptoms be not too urgent, I introduce the principle involved in the modern operation of inguinal colotomy—expose the cerebral cortex, and pack the trephine opening with gauze in order to have the membranes "soldered" off by adhesions. Open the cortex and subjacent abscess cavity in three or four days—earlier if symptoms become urgent. Even twelve hours is sufficient to produce "gluing" of the meningeal margins in those cases in which, owing to the subcortical pressure of the abscess the cortex bulges tensely into the trephine aperture. The second part of the operation I have in several instances performed without anæsthetics. In one such case, operated on in Prof. MACEWEN'S wards in his absence from home, the second portion of the operation was not necessary, the pus finding its own way into the packing through an eroded and sloughy cortex. This, however, is exceptional, and is the only case in which I have met such an event. Secondly, if the symptoms be urgent, and the operation must be at once completed, I have been accustomed, after exposing the cortex and previous to opening the abscess, to rub iodoform powder into the patent meningeal margins

and pack into them, under the edge of the osseous opening, fine strips of sterilised iodoform gauze. This gives a fair degree of security, which is increased if the end of the exploring cannula or drainage tube be brought well out clear of the scalp into aseptic or antiseptic absorbent dressings.

(4) Mr. BALLANCE has spoken of the methods of exploring the brain tissue for abscess. I believe that the surgeon will find it well not to tie himself to any one method. In a recent case in the Glasgow Ear Hospital, the patient had a small cerebellar abscess in the lateral lobe. Having found no "lead" in a very thorough mastoid operation, previously performed by Dr. BARR, I trephined in the usual site, behind and below the sinus, and pushed an exploring cannula forwards and outwards through the cerebellum until it impinged on the petrous bone near the internal auditory meatus—with negative result. I then inserted a pair of forceps in the track of the cannula, and highly viscid pus came away. The patient developed meningitis, and died in ten days. Post mortem we found no meningitis on the posterior aspect of the cerebellum in the region of the trephine opening, but purulent meningitis on the anterior aspect and extending down the cord. This clearly originated in the track of the exploring cannula, which had actually traversed the abscess, and carried with it, to the anterior cortex resting on the petrous bone, pus which was too viscid to flow through its lumen.

(5) Counter-drainage is occasionally advisable. In temporo-sphenoidal lobe, the second opening is readily made in squamous bone or floor of middle fossa as the case may be. In cerebellum, counter-drainage is not so easily secured. In a recent case in which drainage proved inefficient, I made a counter-opening through the petrous bone in the area between sigmoid sinus, superior petrosal sinus, and facial nerve. Details of the case are included in the third edition of Dr. BARR'S "Manual of Diseases of the Ear," p. 316.

(6) Douching the abscess cavity. Formerly I douched enthusiastically. Now I do not douche, or, at least, not

until several days have elapsed after the opening of the abscess, by which time the "soldering" of the membranes has abolished the risk of spilling into the meninges, with consequent meningitis.

Mr. HUGH E. JONES: I quite agree with the last speaker that general surgeons do not always start on the track of the disease in the temporal bone, but are inclined to trust too much to general symptoms and to ignore the localising indications which may be found in the temporal bone.

On the other hand, in starting from the mastoid there is the objection which Mr. COTTERILL has spoken of, of causing sepsis of the other parts which are explored and in which you do not find any pus. I think, however, that this objection, to a large extent, ceases to be a practical one if the mastoid and tympanum are dealt with twenty-four to forty-eight hours before the brain is explored. So far as my experience goes in exploring the temporo-sphenoidal lobe through the tegmen, the drainage afterwards is an extremely difficult matter. I opened a large abscess on one occasion through the tegmen and introduced a large drainage tube, but found it was inadequate. It constantly got blocked and slipped down. In that case I was obliged to operate again from the squamous surface, and ultimately had both openings connected. It is probable that this failure of drainage in the early stage of treatment contributed to the death of the patient.

With regard to the cerebellum, seeing that the abscess is generally in the anterior part and often connected with an extradural abscess on the posterior surface of the petro-mastoid bone, I think that it can be explored more quickly and with much greater ease directly from the mastoid opening than by a separate trephine opening below. But here again, if an abscess is found the difficulty of drainage arises, and to get over this a second opening must be made at the usual site in the occipital bone.

Opening and evacuating the abscess: I am in favour of a large external opening and against syringing. There is one difficulty which still arises when the opening through the

brain tissue is large, viz., the bulging outwards of the inner wall of the abscess to fill the opening before the whole of the pus has been evacuated. I have met the difficulty by passing my finger into the cavity and slowly around its periphery until the cavity was completely emptied.

With regard to diagnosis: How early and how small an abscess which is latent can be discovered? and what is the minimum of symptoms which would justify an exploratory operation? I showed, for a colleague at the International Otological Congress, an abscess the size of a filbert in the temporo-sphenoidal lobe immediately over the antrum, in a case which died of septic thrombosis of the bulb of the jugular vein. One wondered whether so small an abscess as that would give rise to recognisable symptoms; and knowing how easy it is to miss a small encysted abscess, whether it would be wise, supposing symptoms existed, without waiting for urgent symptoms, to try and find so small an abscess, and, if so, what would be the best way of searching for it.

I am not quite clear whether Mr. BALLANCE would thrust the finger through the soft matter of the brain in various directions (using it as a director) in the search for an abscess. Personally I prefer to search for the abscess with a blunt director and to use a narrow knife for incising the capsule.

Dr. MILLIGAN: There are so many interesting points in Mr. BALLANCE'S admirable address that one feels quite sorry one cannot discuss them at some length.

The first point is the question of bacteriological examination. This is important, because in some cases there may be a pure streptococcal infection, and in others the patient is already in a septic state, and I have no doubt that injection of anti-streptococcal serum would give the patient a distinct chance. I have omitted it in some cases and have done it in other cases, and the cure has been proportionately more rapid in the latter. Information can thus be got by bacteriological examination.

With regard to the question of anæsthetics I should like to endorse his remarks. I believe chloroform has to be given very gingerly indeed, especially where the abscess is

suspected to be in the cerebellum. I recorded a case in which I operated on a boy with cerebellar abscess and who had received only a small quantity of chloroform. Respiration entirely ceased, and operation was completed after artificial respiration, with success. Give a fairly stiff dose of brandy half or three quarters of an hour before operation.

All aural surgeons are agreed as to performing a radical operation before the interior of the cranium is explored. Valuable information is given by searching the walls of the cavity, especially if burred down by osteotribes, for where the surfaces are shining one can detect the tracts of pus and get an idea as to whether the abscess lies in the cerebellar or the temporo-sphenoidal lobe.

Speaking from the point of view of an aural surgeon, I have not done more than probably twelve altogether, but the difficulty that I have always had to contend with is that of securing free drainage. The technique we all more or less agree with, and there is no special difficulty in carrying out the operation. The crux is the after-treatment. The difficulty is to prevent the drainage-tube being blocked by sloughing and broken-down tissue. On the last two occasions I made a counter-opening in one case, through the roof of the middle ear, and in the other through the antrum. I put in two drainage-tubes. There is a good deal to be said for counter-opening and free through drainage, so that irrigation can be successfully carried out. The statistics of Dr. TURNER appeal to one on thoroughly practical grounds, and prove the necessity of having a counter-opening, because of the liability of the brain substance to close on itself and prevent free exit.

With regard to the question of delay in operating, this seems to be a most difficult point to decide. Delay in one of my cases was directly responsible for the death of a patient. The moment the patient came into the out-patient room of the hospital, I said she had all the aspects of cerebellar abscess, but on examination I made out nothing very definite. She was carefully watched, and no symptoms appeared for several days, and I thought there was something

wrong with the diagnosis. I operated on the mastoid and cleared it out, and within five days I got a telephone message that the patient had had a sudden maniacal fit. The patient was raving mad, and within an hour or two died. Post mortem a large cerebellar abscess was found, which had burst into the ventricle. One felt that something more ought to have been done. but there were no symptoms justifying opening into the cranium.

I have not been able to understand why hernia cerebri is regarded as a septic condition. I agree with the views of Mr. COTTERILL, and in two cases I removed bone, and the hernia did quite well. I should like to know from Mr. BALLANCE on what grounds he concludes that hernia is the result of sepsis.

I need not delay the Society by any further remarks.

Dr. BARR: Before asking Mr. BALLANCE to reply, I should like to refer to a situation which is, I believe, often neglected in operating upon purulent conditions in the posterior fossa of the cranium. I refer to the posterior surface of the petrous part of the temporal bone, including that area between the lateral sinus and the internal auditory meatus. When there are symptoms of intracranial complication, I am careful to search, in the preliminary mastoid operation, for carious erosions or perforations in the inner wall of the tympanum, because, if such be found, we may suspect that the invasion of the intracranial cavity has taken place through the labyrinthine cavities.

Recently I had a boy with intracranial symptoms, and I observed carious perforations in the labyrinthine wall. These I enlarged, coming upon cario-necrotic *débris* and after working with a Volkmann's spoon inwards and backwards, a considerable flow of pus took place from the direction of the cerebellar cavity. Even supposing there are no evidences of caries on the inner wall of the tympanum, while the use of the trephine over the temporo-sphenoidal lobe and over the cerebellum behind the sinus has yielded negative results, I think we should, before giving up our efforts, carefully inspect the dura mater in front of the sinus, along the

posterior petrous portion of the temporal bone as far as the internal auditory meatus, and search for a possible collection of pus in the anterior part of the cerebellum. No doubt the lesions found there are usually meningeal, or, if cortical, superficial in character, yet in several post-mortem cases I have found in this situation considerable collections of pus in the cerebellum. In our explorations, therefore, this is a region not to be overlooked.

Mr. BALLANCE: I am extremely obliged for the very kind way in which you have received my paper.

Dr. MCBRIDE recommends that a temporo-sphenoidal abscess should be opened through the tegmen tympani. This undoubtedly is the right route when there is an obvious track of disease for the surgeon to follow. But there are other cases without carious erosion of the tegmen, and without certain diagnostic signs of the presence of abscess in the temporo-sphenoidal lobe. If the abscess is not in the temporo-sphenoidal lobe, the surgeon, by working through the tegmina, opens the healthy meninges into the mastoid operation cavity—a cavity which has recently been foul, and which cannot be made surgically clean. On the other hand, an opening away from the mastoid-bone wound may be treated separately without fear of septic infection, if no abscess be present; and if an abscess be found, the tegmina may then with advantage be removed.

Dr. PRITCHARD asks me if I approve of the suggestion of Mr. HORSLEY to use three tubes in cases of brain abscess. My reply is that anything my friend, Mr. HORSLEY, recommends is sure to be good. Nevertheless, there is no royal road to success in the treatment of brain abscess by one, two, or three tubes—the fundamental principles of surgery in the treatment of abscess elsewhere must be carried out in order to win success.

Dr. DUNDAS GRANT and Dr. NICOLL have discussed the question of syringing; and I agree that I am not in favour of even gentle irrigation except in rare and chronic cases. Tubercular abscess would probably be chronic, unless the infection was a mixed one. The acute suppurations caused

by the pneumococcus, streptococcus, and bacillus coli communis, rapidly extend in the brain, as in other parts of the body.

Mr. SECKER WALKER described a case which recovered after three separate openings had been made in the skull for the efficient drainage of the abscess. No case could better illustrate the truth that successful surgical interference in abscess of the brain largely depends on free incision and drainage. Indeed, we must deal with abscess of the brain exactly as we deal with abscess in other tissues of the body.

Mr. SECKER WALKER asked me how the cortex forming the outer wall of a brain abscess can be removed. It is quite easy. The cortex is ligatured in sections with fine silk, and the part within the ligatures can then be cut away without hæmorrhage.

A case illustrating this plan of treatment occurred in a highly gifted man with the usual story of chronic otorrhœa. The discharge was from the left ear. When I saw him he had headache, vomiting, vertigo, optic neuritis, aphasia, alexia, and agraphia, etc. Pus was pouring from the left meatus in quantity, and it turned out, as I suspected, that the brain abscess was discharging through the meatus.

A large area of bone over the temporo-sphenoidal lobe was removed, the limits of fluctuation determined, the cortex ligatured, and the outer wall of the abscess removed. The opening in the brain corresponding to the tegmen was used for drainage. Six months later the patient was met bicycling, and nine months from the operation he resumed his tutorial work.

Mr. COTTERILL has shown us an excellent trephine; I think it corresponds to that recommended by Dr. Hamilton, of America, about 1884.

Mr. STILES suggested that a hernia cerebri should be termed a progressive hernia cerebri; but a hernia cerebri is always progressive in its early stages; hence, why add another word to the description?

I was much interested in the specimen, shown by Mr. Turner, of the membrane which closes a trephine opening.

I have seen the membrane formed months after in the opening made by surgical means in the skull, and have been greatly struck with the strength of it. Nature seems to replace the bone by a strong membrane, and so a protection against injury is afforded.

Dr. NICOLL spoke of the danger of meningitis. In letting out an abscess it is well to pack round with sterilised gauze, as in operations for abdominal suppuration. He spoke of the enormous danger of infective meningitis as the result of evacuating these abscesses, and that, therefore, we should, in selected cases, divide the operation into two stages. Those brain abscesses which I have seen have appeared too urgent for the adoption of this method, and I think it must be very seldom indeed that a case will come before us of an abscess in the brain in which we are able to wait three or four days before opening the membranes and incising the brain. Nevertheless, the suggestion may have a practical bearing on operations in the future. With regard to suppurative meningitis, I do not remember a single case produced by operation. I do not therefore look upon it as a tremendous danger. Probably when it occurs the infection of the meninges has taken place before operation. If a free opening into the abscess be made there is little danger. The danger is greatest when the abscess is treated by puncture, not by free incision.

Dr. HUGH JONES asked if it was dangerous to operate on small abscesses. I should say it is dangerous not to operate. If we can diagnose an abscess we should operate; it does not matter what size the abscess is.

Dr. MILLIGAN has asked when we should operate. I would say that the question of diagnosis is now too large to enter into, but that when the symptoms indicate that suppuration has extended beyond the temporal bone, then an operation should be done.

I must again thank you for your kind reception of my paper.

Dr. BARR: We have now come to the end of this most instructive meeting, and as the sitting has already

lasted so long, I shall not trouble you with any further remarks.

I beg to propose a vote of thanks to the President and College of Physicians and Surgeons for the use of this hall.

The motion was carried unanimously.

EXTRAORDINARY MEETING.

Monday, June 10th, 1901.

THE PRESIDENT, SIR WILLIAM DALBY, IN THE CHAIR.

The PRESIDENT referred, in sympathetic terms, to the death of Mr. STONE, of Liverpool, who was one of the original members of the Society, and a very valued colleague. Most of the members had worked with him, and knew him personally, and a nicer and better man never graced any society. He believed Mr. STONE was not married, or he would have proposed that some notice should be taken of his death by the Society.

The PRESIDENT next expressed the welcome of the Society to Dr. BARKAN, of San Francisco, who was well known by reputation to most of the members. He cordially invited him to consider himself a member for the time being.

The following gentlemen were nominated for election at the next meeting:—

JOHN MALCOLM FARQUHARSON, M.B., C.M. (Ed.), 2 Coates Place, Edinburgh.

ATWOOD THORNE, M.B. (London), 10 Nottingham Place, W.

LESLIE SAMUEL MANNING, M.B., C.M. (Aberd.), Christ Church, New Zealand.

PETER HENDERSON ABERCROMBIE, M.D. (Glasg.), 56 Harley Street, W.

VITRUVIUS HAROLD WYATT WINGRAVE, M.D. (Durh.), 11 Devonshire Street, W.

WILLIAM JOHN CHICHELE NOURSE, F.R.C.S. (Ed.), Abchurch House, Sherborne Lane, E.C.

A case of skin grafting after the complete mastoid operation.

By W. C. Bull.

The operation was performed last July, and had just fallen short of being a complete success, as one spot was still moist. Hearing was now good, whereas it was absent before. For some reason, when the child got out of health one particular carious spot got moist.

The President said the case seemed to him to be a very successful one, and he felt no doubt that the spot would heal, and that no further surgical procedure would be required. The age of the patient was in favour of its healing.

Mr. Cheatle said the middle ear was not quite healed; he thought there would be discharge from time to time, but it was not of great surgical importance.

Mr. Ballance said he had examined the case, and did not think it was moist. The surface was shiny from age and was quite healed.

Post-operative atresia of meatus.

By Richard Lake.

A. F., *æt.* 54, came to hospital in February 1900, with an acute exacerbation of a chronic otitis media suppurativa on the left side. The otitis had been present about fifty years, and, for ten days, acute symptoms, pains, giddiness, with post-aural swelling of four days duration. His temperature was 101° F. He was admitted and the usual post-aural operation performed. The bone was extremely dense, the antrum scarcely demonstrable; the cartilaginous meatus, which was greatly thickened and softened, was removed in consequence, with the exception of the outer third of an inch.

Towards the end of March 1900 the meatus was observed

to be filling up with granulation tissue, which bled readily, and on two occasions small sequestræ came away.

On March 25th, the pinna was again reflected, the granulation-tissue, which sprang from every part of the old operation cavity, removed and kept for examination. The bone was much more freely removed, under the fear that the affection was malignant; and the residuum of the soft tissues of the external meatus entirely removed, so that the index finger passed freely through its external opening.

Pure carbolic acid (fluid) was used to the wound in the bone daily for nearly two weeks, when the wound was allowed to close.

Mr. Lake's colleague, Dr. Jobson Horne, had examined the tissue removed, and reported that there was no sign of malignant disease present; despite every effort, both by plugging and the introduction of a large drainage-tube into the meatus, the whole operation cavity gradually closed up, ending in complete obliteration of the external passages.

Mr. Baber said he had had a case under his care which showed the same difficulty of keeping the meatus open after a Stäcke operation for congenital occlusion.

Dr. Herbert Tilley said he was about to ask whether there was any method to obviate that recontraction, as he had experienced two cases of this kind. One was that of a woman aged 65, who for forty years had chronic suppuration from the ear, but had never had any treatment for it, except that, in order to relieve the slight irritation, she passed a blunt needle into her ear every day of her life. The meatus was so occluded by an exostosis that it was impossible to pass the smallest probe beyond it. Slight facial paralysis had commenced when the speaker first saw the case, and he therefore immediately performed the Stäcke-Schwartze operation. The pus had been pent up behind the obstruction. He was aware of the tendency of the meatus to close after the operation, supposing that it was previously narrowed; and in order to make sure that it should not do so in this case, he cut out a large part of the concha, in the way

Mr. Ballance had adopted in the first part of his operation for skin grafting, and he had even cut it out much more freely than he would have done for the ordinary mastoid operation. After the operation the chief distress of the patient was on account of the very large opening into the ear, which she was certain "would allow of every one seeing into her head." The case had recovered without any bad symptoms, but a few days ago he could pass only a fair-sized probe through the small opening in the meatus. What were they to do in such cases? It was a condition which had to be reckoned with. Ought an opening to be made behind which could be left open permanently? This patient had been advised to pass a bone probe every day, in order to keep the small passage permanently open. If it went on contracting in spite of this, he would advise her to wear a small silver tube, but that would almost certainly irritate. If a method for preventing that after-contraction of an originally narrowed meatus could be elicited, it would confer a great benefit.

Mr. Ballance said he operated on a patient who had complete obstruction of the meatus and obstructive deafness, with a history of having, on two occasions, been given an anæsthetic for the removal of polypus. He had also occasional pain in the ear with giddiness. When he saw the patient, it was a question whether he had not some deep collection which ought to be taken away. He operated as follows: He threw the pinna forward, and then removed a portion of the posterior and upper wall of the osseous meatus, working very slowly inwards, so as not to damage the membrana tympani. He did not know whether the membrane was perforated or not. When he reached the membrane he found that it was quite normal. On its outer side there was a collection of epithelium and inspissated secretion, which had collected there, no doubt, in consequence of the obstruction. The membranous meatus was greatly thickened; and on the opposite side also there was thickening of the membranous meatus and contraction of its lumen. He made a flap similar to that used in the complete mastoid operation for

chronic otorrhœa. The posterior and upper wall of the membranous meatus was then cut away, when it was possible to see almost the whole of the membrana tympani, except a small portion near the anterior border, where the thickened anterior wall of the membranous meatus obscured the view. Ten days later the grafting operation was performed and was completely successful. There was now, if anything, too large a meatus, but the patient was perfectly cured; the hearing had returned, and the pain which he previously suffered had disappeared. Cases like those under discussion might, perhaps, be so treated.

Dr. Dundas Grant said he also had had a case of complete atresia following operation for chronic suppuration of the middle ear, in which there was an extraordinary amount of hyperostosis on the outer surface of the mastoid process. He did a radical mastoid operation, and reproached himself because stenosis followed it. He had, however, to blame the man for leaving the hospital before cure was complete, but he induced him to return and again undergo operation. Again the patient insisted on going out too soon, and the stenosis recurred. He believed there was such a tendency to hyperplasia of the bone that nothing in the form of an ordinary plastic operation would prevent it from narrowing up. Such a case might be a good subject for epithelial grafting, and, if the patient came under care again, he hoped to carry it out, although, with his meatus blocked up, he was much more comfortable than he was before.

Woman, aged 35, in whom an acute mastoiditis has been followed by the spontaneous occurrence of a Stäcke-like operation.

By St. Clair Thomson.

The patient, E. R., was aged 38. In October 1900 she was seized with pain coming on gradually in the left ear. This pain increased until it was quite severe, and was accompanied by giddiness, headache, stiffness and pain in the neck, and pain

radiating along the left side of the tongue. She then had a discharge into her throat of yellow, bad-tasting, and slightly offensive matter. This was followed by a discharge from her ear, and relief of her symptoms.

About six weeks after the above occurrence—that is to say, on December 1st, 1900—she consulted Dr. THOMSON simply from a fear that the severe pain might return. The condition of her left ear was much as it was at the time of exhibition. The bone conduction on that side was good; the whispered voice was heard at a distance of two feet, and the watch on contact. There was no discharge from the ear. Anteriorly was seen the grey remains of the tympanic membrane, limited posteriorly by the malleus. Behind the malleus the fleshy pink covering of the inner wall of the tympanic cavity could be seen. Behind and above, that wall was limited by a definite margin, behind which the eye saw upwards and backwards into the dark grey recess of the antral cavity. The view into the antrum was somewhat interfered with by a fleshy band, which was evidently part of the cutaneous posterior wall of the external meatus. The whole region presented no evidence of desquamation or cholesteatomatous formation.

It would appear that the acute suppuration in the tympanic cavity and antrum first escaped down the Eustachian tube, and then burst through the postero-superior wall of the osseous meatus, carrying with it the incus and all the tympanic membrane lying behind the malleus. In this *débâcle* it swept away some of the bony meatus lying in front of, and also deeper than, the fleshy band which was seen stretching across the entrance to this antro-tympanic cavity.

The case was interesting, as showing a natural method of relief and of guarantee against any further possibility of antral trouble on that side. It afforded also an opportunity for seeing a natural dissection of the region involved.

When the antrum was in the field of vision one could, at the same time, see only a small portion of the tympanic membrane. In securing a more complete inspection of the

antrum the membrane ceased to be visible at the bottom of the speculum.

The patient was seen only once before, six months ago. On examining her again at the meeting, it was seen that there was some secretion from the ear, and therefore the result could not be regarded as a complete natural cure.

Dr. MILLIGAN thought it was not a case in which there had been a primary acute mastoiditis. There was evidence of previous disease of a chronic nature within the ear, and as a result the upper and outer attic wall had become separated; then there had been an acute infection, causing the complete detachment of the sequestrum. The crescent-shaped border in the upper part of the diagram seemed to be the edge of the thickened and adherent membrane, and the cutaneous band running across the diagram was probably a piece of the cutaneous meatus. Behind that, in the posterior angle, there was red mucous membrane, which he thought was still secreting. He did not think the condition was cured, and that was probably why there was some irritation in the tongue. It appeared to be old mastoid disease, with an acute exacerbation and detachment of a localised sequestrum.

Dr. DUNDAS GRANT said the case was a beautiful specimen of a condition which, if not very common, was not extremely rare. He favoured the view, in which Dr. ST. CLAIR THOMSON was not unwilling to acquiesce, that it was an acute exacerbation of an old-standing condition; and he elicited from the patient that probably ten years ago she had been subject to some inflammatory condition in the ear, and that latterly a number of white skins had been extruded. Probably what had formed there was a pseudo-cholesteatoma such as had been so much discussed by the Society. He thought the pressure of the swelling mass of epidermic cells had led to erosion of the outer wall of the attic and postero-superior wall of the meatus, and that this was a fairly successful attempt on the part of the disease to cure by means of epidermisation.

A case of tuberculosis of the temporal bone in an adult.

By Arthur H. Cheatle.

A man, *æt.* 27, came in November last to King's College Hospital with the following history: In the second week in July 1900 the right ear became suddenly deaf after blowing his nose during a cold. The deafness persisted without pain, and seven weeks later he noticed a discharge. Soon after that he had severe pain. In October he went to Golden Square Hospital with a swelling behind his ear and facial paralysis. As there were no beds vacant, he was transferred to King's College Hospital. At the operation extensive caries was found, involving the middle ear, meatus, mastoid process, and the skull over the lateral sinus and part of the cerebellum. The bone was extensively removed, leaving granulating dura mater, to which pure carbolic acid was applied after scraping. Unfortunately no inoculations were made. Tuberculous disease at the right apex was found. A large part of the wound had skinned over, but a sequestrum was in process of separation at the upper part.

Dr. Milligan asked what evidence Mr. Cheatle had that the affection referred to was tuberculous. He understood that the patient was tuberculous, but had the exudation from this particular lesion been examined for tubercle bacilli, or had inoculation experiments been tried? Recently, at the Manchester Infirmary, he saw a case of a very similar nature in a tuberculous man who had a cavity in the lung, but no proof could be adduced of the tuberculous nature of the ear trouble, though bacilli were sought for and inoculation experiments made. He believed the man had a pyogenic infection of the temporal bone, which was not tuberculous. He thought they were not justified in calling anything tuberculous if the specific organism could not be found.

Professor Urban Pritchard said he had seen the case from the beginning, and there could not be the slightest doubt that it was tuberculous. It was very easy to miss

the tubercle bacilli even when they were present. He could not imagine anybody examining Mr. CHEATLE'S case without definitely saying it was tuberculous: seeing it in its healthy condition did not give any idea of the extensive disease which was present. Any one seeing it with the dura mater bare would agree that it was one of the most despairing cases which could be encountered.

Dr. MACKENZIE JOHNSTON asked whether Dr. MILLIGAN attached any practical importance to the discovery of the bacillus. Did that discovery alter in any way the treatment of the case? As the man had undoubted tuberculosis of the lung, it did not, it seemed to him, matter much whether the organism was found in the ear or not, except as a matter of scientific interest. He would have been prepared, on the evidence submitted, to accept Mr. CHEATLE'S statement that the case was tuberculous.

Mr. BALLANCE said the difference between Mr. CHEATLE and Dr. MILLIGAN was important. Dr. MILLIGAN believed the case was not tuberculous and Mr. CHEATLE stated that it was, but without definite proof. They should be very careful about making such statements. A condition should not be said to be tuberculous unless definite evidence of it were forthcoming, either by examination of the granulation tissue or the discharge, or by cutting sections and finding the tubercular structure in the granulations. He thought Dr. MILLIGAN was entirely right. As to the suggestion that it was of no consequence in the treatment, he thought every statement which advanced a real knowledge of the case was of great advantage to the patient as well as the surgeon.

Mr. CHEATLE said his reasons for saying it was tuberculous were that it began painlessly, that there was facial paralysis, and that the condition of the bone, together with tuberculous disease of the lung, warranted the inference. He regretted that inoculation experiments had not been made, but at the same time he thought that tuberculous disease could be diagnosed clinically without the finding of the bacillus.

Mr. R. LAKE confirmed the statement of Mr. BALLANCE that discharges in middle-ear disease in tuberculous patients

were not always tuberculous. At the North London Hospital for Consumption there were many patients with middle-ear disease, but he had never seen one case showing obvious tuberculous disease of the bone.

Mr. CHEATLE said, with regard to the question raised by Mr. LAKE as to discharge from the ear in tuberculous subjects. in King's College Hospital he got many temporal bones of children who had died of tuberculosis, and in many of them he found pus in the middle ear, perhaps without perforation. He had made sections of the lining membrane under these circumstances, and found small-celled infiltration of the deeper layers with casting off of the superficial epithelium, but no evidence of tubercle.

Dr. MILLIGAN said the last place to look for tubercle bacilli was in the pus from the middle ear; there, if bacilli were present, they were much broken up by the action of other organisms, and were not recognisable as such. The place to look for bacilli was at the advancing edge of the disease.

Dr. JOBSON HORNE said that it was more convincing and satisfactory to have a diagnosis based upon positive evidence of tuberculosis; but at times this was difficult to obtain, although the clinical facts might leave no doubt in one's mind as to the nature of the case. This difficulty he had himself met with, not only clinically, but also post mortem. At times at the post-mortem examination of cases of middle-ear suppuration—presumably tuberculous in nature—although there had been no difficulty in obtaining cultures of other organisms, he had been unable to obtain tubercle bacilli (either by film preparation, or by the inoculation of animals with material) from the central portion of the diseased area. He had succeeded, however, in finding the bacilli in the peripheral parts, in sections cut from the soft parts lying immediately over the necrosed bone. From this experience he could readily understand the difficulty that might arise in obtaining positive proof of tuberculosis, more particularly if tubercle bacilli were sought for only in the more central portions of the affected area. The clinical evidence, however,

in cases of tuberculosis of the ear, if at all advanced, was not uncommonly sufficiently pathognomonic, he thought, to permit of the diagnosis being based upon it.

Mr. CHEATLE said he had found only one specimen of tubercle limited to the lining membrane of the middle ear without any affection of bone at all, and that he had shown the specimens and sections before the Society at the last meeting.

A case of mastoid disease accompanied by septic thrombosis of the lateral sinus and post-pharyngeal abscess.

By H. SECKER WALKER.

The patient, a boy of 12, was struck on the head on October 14th last year while fighting. Next day he became ill, and vomited, and the right ear began to discharge. For five weeks he was sick almost every day, and during the last week had three or four rigors daily.

On admission into the Leeds Infirmary on November 20th a fluctuating swelling on the right mastoid was found, and it was ascertained from the parents that there had been intermittent right otorrhœa since infancy. Mr. W. H. BROWN, the surgeon under whose care the case was admitted, asked Mr. WALKER to see the case with him in consultation, and then transferred him to his wards for treatment.

The child was very ill and emaciated, irritable, and resented being touched or examined. The right pinna was pressed forwards by a soft, tender swelling on the mastoid, and there was a foul-smelling discharge from the meatus. There was a left internal strabismus which, however, was found to be concomitant and of long standing. No optic neuritis was present, and the movements of the pupil were normal. The knee reflexes were good, and there was no paresis of the face or limbs. The back was slightly arched and rigid as he lay in bed, but there was no spinal tenderness. The tongue was dry; the bowels open, twice daily; urine alkaline, containing large deposit of pus and phosphates. Since admission,

twenty-four hours earlier, there had been one severe rigor, but no vomiting. Temperature 104°, pulse 112.

He decided to open the mastoid antrum and middle ear in order to examine the lateral sinus. On chiselling the outer wall of the mastoid away, a large abscess cavity was opened, full of very fœtid pus, which pulsated synchronously with the pulse. After clearing this, the middle and antrum were thrown into one cavity and cleaned. Several small sequestra formed the posterior wall of the abscess cavity, and the bone almost up to the internal auditory meatus was diseased, discoloured, and had to be removed. A considerable surface of the dura mater in the posterior fossa, covered with granulation tissue, was thus exposed. An inch of bone over the lateral sinus was chipped away from the outer surface of the skull, and the sinus exposed and then opened with a fine scalpel. Its interior was filled with clot undergoing putrefaction. The clot was removed and the sinus wall gently scraped clean, the scraper being introduced up the vein, and the clot gently detached, until there was free hæmorrhage. As far as possible all the clot was removed, and then the hæmorrhage was stopped with a gauze plug.

The lower end of the sinus was scraped and cleaned, and the whole wound swabbed with pure carbolic acid. The meatus was split along the floor and turned upwards. Two days later the dressing was removed: that from the upper end of the lateral sinus was slightly discoloured and fœtid. The boy was drowsy and irritable at times, though much better than before the operation. Temperature 98°, pulse 76. No further vomiting or rigors. Three days later vomiting began, headache was very severe, and he was more drowsy.

There was slight swelling of the right optic disc, and the head was rather retracted. Temperature 103°.

The patient was brought down to the theatre and the dressing removed. The gauze in the upper part of the lateral sinus was rather fœtid, that in the lower end of the sinus and in the middle ear quite sweet, while the dressing deep in the mastoid was rather offensive. Some bone here was found discoloured and chiselled away. The

whole length of the lateral sinus was exposed by chiselling away a channel in the bone up to within half an inch of the external occipital protuberance, and the sinus opened up to this point, when profuse hæmorrhage occurred, easily controlled with a gauze plug. The upper part of the vein contained septic clot. The whole length of the interior of the sinus was thus exposed, and scraped and scrubbed with pure carbolic acid.

A gauze plug was laid in the sinus, the middle ear and antrum packed, and the skin sutured over, except over the mastoid cavity, where it was kept open with gauze.

During the two following days the patient had a rigor and the temperature rose to 103° and then 106°; pulse 132.

A swelling was now found at the upper part of the neck, just below the ear, which was tender to the touch. Up to now there had been no tenderness in the neck. An incision three inches long was made over the swelling, but no pus was found until the transverse process of the atlas and the deep cervical vessels were exposed. On passing a probe beneath the latter, towards the middle line, it entered a cavity, containing half an ounce of pus, apparently a post-pharyngeal abscess. Free drainage was secured by a rubber tube. The occipital incision had healed perfectly. After this we had no serious trouble; the temperature fell to normal; the boy brightened up, asked for food, and displayed great interest in the betting column of the evening papers.

In a fortnight's time, December 16th, the grafting operation was performed on the antrum and middle ear, the granulations in which were exuberant and had to be scraped; but as far as he could tell, the osseous walls were healthy.

This was probably a mistake, for a portion of the graft which lined the middle ear did not become adherent, and there was some discharge of pus for a few weeks from this part. The hinder portion in the mastoid process, and where it was in contact with the dura mater, did excellently, and was dry when the gold-leaf and dressing were removed on the fifth day.

The boy rapidly gained strength and got quite stout, the only drawback being the continued slight otorrhœa, which, however, was explained in the eighth week after the last operation by the appearance of a small sequestrum, which was unfortunately lost before he saw it. The following day a sequestrum of the lower turn of the cochlea was removed from the middle ear.

Almost immediately the otorrhœa ceased, and the inner wall of the middle ear rapidly covered with epithelium.

He examined the patient on June 7th—*i.e.*, fourteen weeks after his discharge from the hospital.

The present condition was interesting. No grooving can be felt where the bone covering the lateral sinus was removed. There was the curved scar of the mastoid incision behind the ear, and a linear one in the neck where the pharyngeal abscess was drained.

The mastoid cavity had filled up, so that there was no indication of the large cavity which appeared there during the operations; and after touching with a probe, he believed a dense wall of new bone had grown up and filled the mastoid process, thus removing what he looked upon as a possible future danger, viz., the liability of an injury to the dura mater and cerebellum through the enlarged meatus. The attic and antral roof and the inner wall were lined with glistening pink epithelium.

Although the patient had lost a considerable part of the cochlea, yet he could hear very remarkably with this ear. When the left ear was plugged he heard a moderately raised voice at three feet from the right ear, Galton's whistle in all its ranges at one foot, and the tuning-fork with vibrations from 128 to 2048 per second at six inches. A watch was not heard on contact. To be quite certain that he did hear the tuning-fork, the patient was made to sing the notes he heard, and he sang them fairly well.

The President said this was the second case recorded in aural surgery in which part of the cochlea had come away, and in which the patient was said to have heard

fairly well afterwards. The first was published in 1874, and was under the care of Mr. CASSELLS, of Glasgow. It was also seen and referred to by the late Mr. HINTON.

Mr. R. LAKE said possibly the same explanation might be applied to these cases as of deaf mutes learning to hear. By some means the brain apparently acted in some of the cases without any intermediary apparatus. In dissections of deaf mutes the labyrinth was not all present, or had only been partially formed. He believed a third case of the present kind was recorded by Goldstein.

Professor URBAN PRITCHARD said he remembered Cassells' case, and thought part of the cochlea was left. The question in the present case was whether the whole cochlea came away. As it was a very important matter, could Mr. WALKER bring the case before the Society for careful testing?

Mr. SECKER WALKER replied that he had made the tests very carefully, being aware that it was a very rare condition. A small piece of sequestrum was lost before he saw it; and this might possibly have been a further portion of the cochlea. He would bring the case up for testing, as suggested.

Notes, with specimen and microscopical sections, of two cases of carcinoma of the external auditory meatus.

By ADOLPH BRONNER.

(1) S. *æt.* 46. The left ear had been swollen, painful, and discharged for two or three years. Two years ago an abscess burst behind the ear. Ear fixed and not movable. Meatus was closed, and painful on pressure. Thickening of tissues behind ear, with fistula. Removed January 24th, 1901.

The Clinical Research Association reported:

"The fragments from the ear are infiltrated with branching processes of squamous-celled epithelioma. There are a few cell nests."

(2) F. *æt.* 79, July 1900. The right ear had discharged for five or six months. A polypus is said to have been removed

two months ago. Meatus closed and hard. Ear generally hard, and not freely movable. Removed July 30th, 1900.

The Clinical Research Association reported:

"These sections exhibit a soft carcinomatous growth, infiltrating a portion of the parotid salivary gland. The tissue is much shrunk by the action of too strong formalin solution, and therefore the details of the growth are not satisfactory."

Case of fatal hæmorrhage from the ear, with specimen.

By W. Milligan.

The patient, a girl aged 2½ years, was admitted to hospital on account of a recent and severe hæmorrhage from the ear. On admission the temperature was 101·2; pulse 96, and respirations 44. At the angle of the jaw there were several enlarged glands, and the tonsil upon the same side—the right—was also enlarged. The right membrana tympani was perforated. There was no sign of any mastoid disease. The child had suffered from suppurative middle-ear disease for over one year.

Shortly after admission a severe attack of hæmorrhage took place. The external auditory meatus was accordingly tightly packed with cyanide gauze and the child was kept quiet in bed.

Ten days later another severe attack of bleeding took place. In consequence of this Mr. H. Lund tied the right common carotid artery. Two days later, however, very severe hæmorrhage took place from the nose, mouth, and ear, to which the child succumbed.

At the post-mortem examination no necrosis was found in the tegmen tympani or the pars petrosa. An abscess cavity was found under the temporal bone communicating with the external auditory meatus by a fistulous track between its cartilaginous and its bony portions. The abscess cavity was full of recent blood-clot, and in it lay the internal carotid artery, ulcerated and sloughy.

Dr. MILLIGAN asked whether members thought it advisable in such a case to tie both common carotids. In the case he had just described the common carotid was tied successfully, and the recurrent hæmorrhage was through the anastomosis in the circle of Willis.

Mr. CHEATLE said a short time ago, in the *British Medical Journal*, SPENCER, of the Westminster Hospital, described a case of hæmorrhage from the ear in which he tied the common carotid, with success. SPENCER thought the hæmorrhage came from a twig of the internal carotid; but there could be no doubt that it came from the internal carotid itself.

Notes of a case of temporary loss of audition and equilibration from an overdose of quinine.

By URBAN PRITCHARD.

Dr. PRITCHARD said that the effect of large doses of quinine on the hearing power is so well known that he should not have troubled the Society with the following case had not the deafness been accompanied with loss of the other function of the internal ear, namely, equilibration; or, in other words, the case exhibited more or less complete paralysis of the nerve terminations of the posterior as well as of the anterior portion of the labyrinth.

This effect of quinine on the function of equilibration had not hitherto been noticed or published, so far as he had been able to discover. But as "there is nothing new under the sun," he was quite prepared to learn from some members of the Society that, through his defective acquaintance with the literature of the subject, he had missed several similar cases already published. In fact, his chief reason for calling attention to the case is to seek information on the subject from his colleagues.

The following are some short notes of the case:

Mrs. W. B., *æt.* 40, a very accurate patient, recently gave the following history: Four years ago, when she was in the

habit of taking three-grain doses of quinine for neuralgia, she awoke one night between two and three o'clock with neuralgia, and her husband gave her what he thought was the usual dose of quinine; but he emptied the bottle, and evidently gave a large overdose, though, even at the highest computation, it must have been under sixty grains.

She went to sleep again, and awoke a second time between six and seven A.M., having lost the neuralgia, and feeling quite well. She got out of bed, and then found that she had so completely lost the sense of equilibrium that she could not walk, but fell about and was not even able to stand. There was no vertigo, nausea, or vomiting; but she found herself stone deaf, and there was severe buzzing tinnitus.

She managed to get into bed, and then felt comparatively well again, except for the tinnitus and deafness. She remained in bed, and the loss of equilibrium completely passed off in about five hours; the hearing returned in eight to ten hours, and the tinnitus disappeared in about forty-eight hours.

The patient stated that she had been slightly deaf with the right ear before, and thought there had been a little increase of the deafness ever since.

She came to Dr. PRITCHARD for this defective hearing.

He found the left ear normal; the watch-hearing distance on the right side 12 per cent. increased on inflation (Politzer's) to 18 per cent.; the voice was heard comparatively rather worse than the watch. The tuning-fork (medium C) applied to the bridge of the nose was heard all in the right ear. The membranes were fairly normal in appearance, the nose and naso-pharnyx only showed a little chronic catarrh of the mucous membrane. In short, there was some middle-ear catarrh, but apparently no sign of any nerve deafness.

The hearing rapidly improved under ordinary catarrhal treatment; so that we may take it for granted that the overdose of quinine left no permanent effect whatever.

He considered that this was a typical case of temporary loss of both functions of the ear. The absence of vertigo and nausea showed that there was no irritation of the nerve terminations,

but a pure paralysis. The tinnitus was probably caused by vascular changes produced by the quinine. For although there is difference of opinion as to the mode of action of the drug on the internal ear, yet, if we may judge from analogy of the eye, where the effect on the vessels can be seen, it acts by producing temporary anæmia.

It was interesting to note that the loss of equilibration passed off first, the deafness next, and the tinnitus long after the other two. He thought this was just what would be expected, because, undoubtedly, quinine affects the hearing power much more readily than the sense of equilibration; and although possibly the hearing power was somewhat defective for a longer time than the patient supposed, yet it would be expected that the disturbance of the circulation would only gradually subside, and that therefore the tinnitus would persist longer than, at any rate, the extreme deafness.

In reply to Dr. Barkan, he said no quinine amblyopia was noticed. He had never previously heard of equilibrium being interfered with by quinine.

Dr. Dundas Grant suggested that the quinine produced congestion of the auditory nerve. In several cases of quinine tinnitus he had tried the effect of compressing the vertebral arteries in the suboccipital region, and had been able to diminish the tinnitus, which he took to be evidence of congestion.

A red vegetable growth from the ear.

By L. A. Lawrence.

The patient, a boy of 21, was brought to Mr. Lawrence last January on account of deafness, of some duration, which had been getting worse lately. He was the son of a small farmer in Devonshire, and was injured in driving a cart. On examination of his right ear, Mr. Lawrence observed a condition of redness at the bottom of the meatus, which caused him to ask the boy if he had been putting a pin into his ear. The appear-

ance through the speculum was one of quite recent hæmorrhage. The patient said he had put a pin in, and when asked if he had hurt himself with it, he replied in the negative. Inquiry as to the history of discharge from the ear was also answered in the negative. On washing the ear out with the syringe the whole contained red mass came away, leaving the membrana tympani clearly in view and rather retracted and slightly dull. The mass which came away was convex on its inner side, where it had been in contact with the drum membrane, white, dull, and slightly glistening; on the other side the mass was red, very much the colour of blood, and the red growth was about a twelfth of an inch thick, so that the side exposed to the air was not so concave as that in contact with the drum membrane. The examination of the left ear revealed the same sort of condition as was present on the right side. He endeavoured to remove a piece of the growth with forceps, but the process appeared so painful to the patient that he desisted, and gave him some biniodide of mercury lotion (1×4000) to use for a day or so. Four days later both ears were in the same condition in which they had been left, and the case was altogether such a curious one that Mr. CUMBERBATCH saw the case with him. The left ear was syringed out, with the same result as the right. The growth came away easily, and was of the same form, colour, and size as that which was removed from the right ear. Unfortunately the deafness was not in any large degree relieved by removal of these growths, and in a letter he had lately had from the patient he expressed himself as being in about the same condition. The growth itself was kindly examined by Dr. ANDREWES in the laboratory at St. Bartholomew's Hospital. He inoculated tubes of different media with the growth for two weeks. Nothing took place except the development of ordinary forms, which were to be expected. At the end of that time a potato culture evidenced growth and showed a thin white mould. This grew for some ten days as a white mould and then turned red. Other media were inoculated from this tube, and eventually Dr. ANDREWES was able to

make out the following interesting particulars: The growth consisted of, firstly, a mere core-like growth, which, in its pure state, retained a white colour; secondly, of a coccus, which also continued white, though culture had not yet brought it to quite a pure condition. Each component, therefore, when grown separately was white, but when grown together after a time they became red.

The specimen marked *a* was that of the mucous-like growth showing a mycelium and some globular fruit capsules.

Notes of a case of papilloma of the auricle, with specimen and macro- and micro-photograph.

By P. Macleod Yearsley.

The patient was a woman, *æt.* 62, and the growth had been noticed for a little over four years. It began on the inner surface of the antitragus of the left pinna as a small warty excrescence. Up to the last six months it had grown very slowly, but had developed rapidly since. The photograph shows well the size of the papilloma, which nearly filled the whole concha. It was removed under chloroform by a free elliptical incision, the cartilage beneath it being excised as well. The wound healed perfectly in three weeks, leaving a linear scar and no noticeable deformity.

Microscopic examination, as can be seen by the specimen shown, proved the growth to be a pure papilloma.

The specimen was chiefly remarkable for its size, as it measured over an inch in its longest diameter.

Central necrosis of a portion of the semi-circular canals.

By W. C. Bull.

This specimen was removed from the petrous bone of a boy, *æt.* 10, who had suffered from otorrhœa for some years.

When first seen there was offensive purulent discharge from the right ear but no facial paralysis.

Fig. 8.

Papilloma of the auricle.

Mr. MACLEOD YEARSLEY

A fortnight afterwards the boy was brought to St. George's Hospital with high temperature (103°), profuse offensive discharge, intense pain, and complete facial paralysis.

The complete mastoid operation was performed on April 28th, 1900, and an opening found leading from the tympanic cavity into the petrous bone. This was enlarged, and a large cavity extending to the internal auditory meatus was exposed which contained the sequestrum produced. The ear healed perfectly by granulation.

Deafness was complete, and the facial paralysis had remained permanent.

The specimen consisted of a portion of the internal ear, and showed the union of the superior and posterior semi-circular canals, with the common opening into the vestibule. He thought that the small orifice might be for the passage of vessels or nerve tissues, or might have some relation to the aqueductus vestibuli. The exact nature of the opening was doubtful, and he would be glad if the Society would allow the secretary or a sub-committee to report on the specimen.

Specimen of exfoliation of the cochlea.

By C. H. Fagge.

E. C., *æt.* 4, suffered from painless otorrhœa for fifteen months previous to July 12th, 1900, when Mr. Fagge performed the radical mastoid operation on her for suspected tuberculous middle-ear disease. The disease, which had resisted a year's antiseptic treatment besides removal of polypi, was found to be due to extensive caries in the region of the antrum, and in removing a large area of carious bone the facial nerve was injured. Facial paralysis was complete, and the post-auricular wound healed primarily. Discharge became thin and odourless, and she was discharged a month after operation, the wound still packed. Otorrhœa continued, and a polypus was removed, only to be followed by another, which, on December 15th, under an anæsthetic, was removed per meatum, and curetted out three pieces of the inner wall of

the middle ear, one of which, showing a half-turn of the cochlea, was the specimen shown. The meatus was again packed, and, after being dressed every three days until January 15, was well healed.

This condition persisted: no pain; hearing nil, either aerially or on mastoid.

INDEX.

PAGE

ABBOTT (F. C.), case of sarcoma, probably primary, of the Eustachian tube 18
Abscess, the operative treatment of, when situated in the brain (C. A. Ballance) 80
—— temporo-sphenoidal, case of (H. E. Jones) . . . 67
—— of mastoid, case of (P. De Santi) 32
—— extra-dural and cerebellar, fatal case of (C. H. Fagge) . 43
—— post-pharyngeal, case of (H. S. Walker) 126
Atresia of meatus, post-operative, case of (R. Lake) . . . 117
Auricle, papilloma of (P. M. Yearsley) 36
—— pigmented warty growth of (R. Lake) 65

BABER (C.), remarks 24, 118
BALLANCE (C. A.), on the operative treatment of abscess when situated in the brain 80
—— acute temporal bone septicæmia 37
—— remarks . . 8, 16, 17, 25, 40, 55, 60, 112, 117, 119, 124
—— and MILLIGAN (W.), a new electrical motor . . . 7
BARKAN (Dr.), remarks 134
BARR (T.), remarks 97, 111
Bone, temporal, case of acute septicæmia of (C. A. Ballance) . 37
—— —— specimen in which the tendon of the tensor tympani was absent (R. Lake) 65
Brain, operative treatment of abscess in the (C. A. Ballance) . 80
—— case of bullet wound through (Sir William Dalby) . 43
BRONNER (A.), microscopical section of epithelioma of cutaneous external meatus which was at first mistaken for mastoid disease 39

PAGE

BRONNER (A.), notes, with specimen and microscopical section of two cases of carcinoma of the external auditory meatus . 130
—— remarks 14, 40, 53
BULL (W. C.), case of skin grafting after the complete mastoid operation 117
—— —— central necrosis of a portion of the semi-circular canals 136
—— remarks 14
Bullet wound through brain and cerebellum, case of (Sir William Dalby) 43
—— —— closing meatus, case of (C. H. Fagge) . . . 37

Canals, semi-circular, central necrosis of a portion of (W. C. Bull) 136
Carcinoma of meatus, two cases of (A. Bronner) . . . 130
Caries of petro-mastoid in a case of otitis media (H. E. Jones) . 73
—— necrotica, of outer antral wall, specimen of (R. Lake) . 65
CHEATLE (A. H.), case of internal ear deafness, perversion of taste, and facial paralysis associated with herpes of the neck 6
—— specimen and microscopical section of a case of tuberculosis of the middle ear lining membrane from an infant . 42
—— specimen of a gap in the handle of the malleus, probably congenital 42
—— case in which the complete post-aural operation was performed 50
—— case of tuberculosis of the temporal bone in an adult . 123
—— remarks 8, 12, 15, 20, 35, 41, 46, 58, 62, 66, 117, 124, 125, 126, 132
Cholesteatoma, two cases of (D. Grant) 23
—— case of (P. De Santi) 31
Cochlea, specimen of exfoliation of (C. H. Fagge) . . . 137
COTTERILL (J. M.), remarks 100

DALBY (Sir William, President), case of bullet wound through brain and cerebellum, leaving no after effects beyond loss of hearing on one side 43
—— remarks 14, 20, 30, 35, 40, 52, 58, 117, 129
Deafness of the internal ear associated with herpes of the neck, case of (A. H. Cheatle) 6

PAGE
Deafness bilateral, in a case of cerebral tumour (C. H. Fagge) . 8
Diagrams to explain Weber's and Rinne's tests (D. Grant) . 61

Emphysema, gangrenous, of scalp tissue in a case of mastoid abscess (P. De Santi) 32
Epithelial grafting after mastoid operation (H. Tilley) . . 15
Epithelioma of meatus simulating mastoid disease (A. Bronner) 39
Equilibration, temporary loss of, from overdose of quinine (U. Pritchard) 132
Eustachian tube, case of sarcoma of (F. C. Abbott) . . . 18

Fagge (C. H.), case of cerebral tumour associated with bilateral deafness of nervous nature 8
—— a fatal case of extra-dural abscess and cerebellar abscess . 43
—— case of closure of meatus following a Mauser bullet wound 57
—— specimen of exfoliation of the cochlea 137
—— remarks 13, 14, 59, 78
Foreign body in meatus 26 years, case of (St. Clair Thomson) . 66
Fripp (A. D.), quoted 57

Grant (D.), case of cholesteatoma treated by the radical mastoid operation, with preservation of the lining membrane and Körner's plastic flap 23
—— —— —— and with resection of cartilage 23
—— diagrams for the explanation of Weber's and Rinne's tests 61
—— remarks 25, 34, 53, 56, 59, 99, 120, 122, 134
Growth, red vegetable, from the ear, case of (L. A. Lawrence) 134

Hæmorrhage, aural, fatal case of (W. Milligan) . . . 131
Hernia cerebri in a case of suppurative otitis media (H. E. Jones) 67
Herpes of the neck associated with internal ear deafness, case of (A. H. Cheatle) 6
Hill (W.), remarks 14, 24, 35
Horne (J.), remarks 125

PAGE

Incus, case of tuberculous disease of (W. Milligan) 49

JOHNSTON (M.), remarks 124

JONES (Hugh E.), case of suppurative otitis media, temporo-sphenoidal abscess: operation: hernia cerebri: maniacal excitement: recovery 67

—— case of suppurative otitis media: caries of petro-mastoid: facial paralysis: curetting operation: death from convulsions twenty-eight hours later 73

—— remarks 63, 77, 78, 108

Labyrinth, case of injury to (P. M. Yearsley) 36

LACK (L.), case of acute meningitis following suppurative otitis media: operation: recovery 61

—— remarks 59, 62

LAKE (R.), case of double ossiculectomy for chronic middle ear suppuration 13

—— specimen of temporal bone in which the tendon of the tensor tympani was absent 65

—— specimen of pigmented warty growth from the auricle of a woman, aged 50 years 65

—— specimen showing caries necrotica of the outer antral wall from a child, aged 4 years 65

—— case of post-operative atresia of the meatus 117

—— remarks 15, 124, 130

LAW (E.), remarks 59

LAWRENCE (L. A.), a red vegetable growth in the ear . . 134

—— remarks 67

MCBRIDE (P.), remarks 24, 35, 97

MACNAUGHTON-JONES (H.), severe aural vertigo treated by operation: cure 26

—— remarks 40, 60, 66

Malleus, specimen of gap in handle of (A. H. Cheatle) . . 42

Maniacal excitement in a case of otitis media (H. E. Jones) . 67

Mastoid disease with septic thrombosis of lateral sinus, etc. (H. S. Walker) 126

—— operation, skin grafting (W. C. Bull) 117

—— —— for disease of epitympanum (W. Milligan) . 29

—— —— multiple epithelial grafting after (H. Tilley) . 15

PAGE

Meatus, epithelioma of, simulating mastoid disease (A. Bronner) 39
—— two cases of carcinoma of (A. Bronner) 130
—— case of atresia of (R. Lake) 117
—— —— removal of impacted sequestrum of (U. Pritchard) 47
—— foreign body in for 26 years (St. Clair Thomson) . . 56
Membrane, Shrapnell's, case of perforation of, treated by ossiculectomy (St. Clair Thomson) 34
Meningitis, acute, in a case of otitis media (L. Lack) . . 61
Middle ear, case of tuberculosis of (A. H. Cheatle) . . . 42
Milligan (W.), case in which the radical mastoid operation was performed for chronic suppurative disease of the epitympanum and adjoining mastoid cells 29
—— case of tuberculous disease of the incus 49
—— —— fatal aural hæmorrhage, with specimen . . . 131
—— remarks . . 8, 12, 14, 59, 66, 77, 109, 122, 123, 125, 132
—— and Ballance (C. A.), a new electrical motor
Motor, a new electrical (C. A. Ballance & W. Milligan)

Neck, herpes of, associated with internal ear deafness, case of (A. H. Cheatle) 6
Nicoll (J. H.), remarks 104

Ossiculectomy, case treated by (R. Lake) 13
—— —— (St. Clair Thomson) . . . 34
Otitis media, suppurative, case of (H. E. Jones) . . . 67, 73
—— —— —— —— (L. Lack) 61
—— —— —— —— (R. Lake) 13

Papilloma of auricle, case of (P. M. Yearsley) 136
Paralysis, facial, in a case of internal ear deafness (A. H. Cheatle) 6
—— —— —— otitis media (H. E. Jones) . . 73
Petro-masoid, caries of, in a case of otitis media (H. E. Jones) 73
Post-aural operation, case of (A. H. Cheatle) 50
Pritchard (U.), notes of a case of removal of an impacted meatal sequestrum facilitated by previous decalcification . 47
—— notes of a case of temporary loss of audition and equilibration from an overdose of quinine 132

PAGE

PRITCHARD (U.), remarks . . 25, 41, 52, 56, 60, 66, 98, 123, 130

Quinine, overdose of, inducing temporary loss of audition and equilibration (U. Pritchard) 132

SANTI (P. DE), case of cholesteatoma of mastoid : radical cure . 31
—— case of mastoid abscess : extensive gangrenous emphysema of scalp tissues : attico-antrectomy : cure 32
—— remarks 59, 60, 78
Sarcoma of Eustachian tube, case of (F. C. Abbott) . . 18
Sequestrum, impacted meatal, case of (U. Pritchard) . . 47
Skin grafting after mastoid operation, case of (W. C. Bull) . 117
SPENCER (W. G.), quoted 132
Stacke-like operation, spontaneous occurrence of (St. Clair Thomson) 120
STILES (H. J.), remarks 103

Taste, perversion of, in a case of internal ear deafness (A. H. Cheatle) 6
Tensor tympani, absence of tendon of (R. Lake) . . . 65
Tests, Weber's and Rinne's, explanatory diagrams of (D. Grant) 61
THOMSON (ST. CLAIR), case in which ossiculectomy was performed for perforation and cholesteatomatous formation in Shrapnell's membrane 34
—— case of a foreign body which had remained innocuously in the meatus for 26 years 66
—— case of a woman, *æt.* 35, in whom an acute mastoiditis had been followed by the spontaneous occurrence of a Stacke-like operation 120
—— remarks 35
TILLEY (H.), case of multiple epithelial grafting after the radical mastoid operation 15
—— remarks 17, 41, 118
Tuberculosis of middle ear, case of (A. H. Cheatle) . . . 42
—— incus, case of (W. Milligan) 49
Tumour, cerebral, with bilateral deafness, case of (C. H. Fagge) 8
TURNER (L.), remarks 104

PAGE

Vertigo, severe aural, cured by operation, case of (H. Macnaughton-Jones) 26

WALKER (H. S.), case of mastoid disease accompanied by septic thrombosis of the lateral sinus and post-pharyngeal abscess 126
—— remarks 54, 100, 130

YEARSLEY (P. M.), case of injury to the labyrinth . . . 36
—— notes of a case of papilloma of the auricle, with specimen and macro- and micro-photograph 136
—— remarks 35

Printed by BALLANTYNE, HANSON & Co.
London & Edinburgh